

The Comparison of Success Rate of Two Techniques of Pneumatic Retinopexy

Muhammad Arif, Qamar Mehboob, Muhammad Nawaz Malik

ABSTRACT

Objective: The present study was conducted to see the outcome of two different techniques of Pneumatic Retinopexy to treat the cases of fresh rhegmatogenous retinal detachment. **Study Design:** It was a prospective interventional study. **Settings:** This study was conducted at two different centers; Diagnostic & Research Centre, Department of Ophthalmology Allied hospital Faisalabad and Lahore Eye Care Center, Faisalabad. **Duration:** From June 2016 to June 2018. **Methodology:** Total twenty patients were included according to the inclusion and exclusion criteria. Twelve were male and eight were female patients. These patients were divided into two groups; group A and group B. In group A 0.5 ml SF₆ pure gas was injected in vitreous cavity after applying transconjunctival cryo at the retinal breaks and in group B 0.5 ml SF₆ was injected intravitreally without cryo application. **Results:** In group A success rate was 90% and in group B success rate was 50%. **Conclusion:** Transconjunctival cryo application at retinal breaks markedly increases the success rate of pneumatic retinopexy for the treatment of cases of fresh rhegmatogenous retinal detachment. **Keywords:** Pneumatic retinopexy, Cryo, Rhegmatogenous.

Corresponding Author

Submitted for Publication: 17-12-2018

Accepted for Publication: 16-06-2019

DR. MUHAMMAD ARIF, Associate Professor, Ophthalmology Department, Faisalabad Medical University, Faisalabad-Pakistan.

Contact / Email: +92 301-7052757, qamarmehboob89@yahoo.com

Citation: Arif M, Mehboob Q, Malik MN. The comparison of success rate of two techniques of pneumatic retinopexy. APMC 2019;13(2):185-7.

INTRODUCTION

Pneumatic retinopexy (PR) is a surgical (Outdoor) technique to treat the fresh cases of rhegmatogenous retinal detachment. In this technique we inject different types of intravitreal gases like air, C₃F₈, SF₆. For the last 35 years¹, the primary retinal detachment is mostly treated by scleral buckling, although other surgical procedures like cryopexy, vitrectomy, laser, pneumatic retinopexy were also performed.

PR is a two-stage surgical procedure. In its first stage, air or an expanding gas bubble such as sulfur hexafluoride (SF₆) or octafluoropropane (C₃F₈) is injected into the vitreous cavity. In its second stage, cryo, laser or both are applied. The patient is instructed to have a specific head position so that the gas bubble closes the retinal break and the subretinal fluid (SRF) is reabsorbed. Some surgeons do the procedure in clinic room with patient sitting on the chair, while others do in proper operation theater with patient lying in supine position.

In 1938,² for retinal detachment repairing, Rosengren introduced retinopexy with gas endotamponade. It was followed by Hilton and Grizzard (1986)³, who published it as modern pneumatic retinopexy. The time changed and small-gauge vitrectomy became the standard today. In this situation, has pneumatic retinopexy, with or without cryo, any role? To find out the answer of this question, we conducted the present study.

Review of Literature: To treat retinal detachment, Pneumatic retinopexy, is one of the best methods which is non incisional and minimally invasive. Previously because of lack of proper knowledge about different aspects of the technique, surgeons believed that it did not relieve vitreoretinal traction. Moreover, it requires more preoperative time not only for detailed fundus examination with its breaks but also to educate the patient.

Norton in 1973,⁴ injected sulfur hexafluoride to treat retinal detachment and reported good results. While, Vygantas et al⁵ performed same procedure with perfluorocarbon gas injection. In 1974, Fineberg E et al,⁶ injected sulfur hexafluoride into rabbit's eye and found no gross toxicity. In 1985, it was proved that retina can be reattached with vitrectomy and fluid/gas exchange without scleral buckling by Escoffery et al⁷. Time passes and more and more ophthalmologists became aware of advantages of pneumatic retinopexy. Now PR has become widely accepted as 87% of vitreoretinal surgeons favor this technique⁸.

METHODOLOGY

Study Design: Prospective Interventional Study.

Settings: Diagnostic & Research Centre, Department of Ophthalmology Allied hospital Faisalabad and Lahore Eye Care Center, Faisalabad-Pakistan.

Duration: Two years from June 2016 to June 2018.

Inclusion Criteria: All phakic patients who presented with fresh retinal detachments. Having one or more retinal breaks within one clock hour of superior half of fundus. Macula "on" and "off" both types were included. Cooperative patients who were willing to maintain specific head posture postoperatively

Exclusion Criteria: All aphakic and pseudophakic patients. All cases having PVR grade C or D. Known cases of advanced glaucoma. Patients having media opacities. Patients feeling difficulty to maintain specific head posture

Methods: Total 20 patients were included in this study. Out of these patients, 12 were males and 8 were females. The age of the patients was from 23 to 71 years with an average of 41.79 years.

Groups: These patients were divided into two main groups; Group A and Group B, each group comprising of ten cases. In Group A, every patient underwent transconjunctival cryopexy at the retinal breaks followed by intravitreal injection of 0.5ml pure SF6 gas. In Group B only intravitreal injection of 0.5 ml pure SF6 gas was injected without applying cryo at retinal breaks. All cases were done in proper eye operation theaters, under topical proparacaine eye drops and peribulbar injection of 2% lidocaine. The pupil was well dilated with 1% tropicamide and 10% phenyl ephrine eye drops. All procedures were done with the patient lying on the operation table in supine position.

Procedure: In group A patients transconjunctival cryopexy was applied at retinal breaks with the help of indirect ophthalmoscope and 20 D convex lens. Then in both groups 0.5 ml SF6 pure gas was injected in the vitreous through pars plana, 4 mm away from the limbus at inferotemporal quadrant by the same assistant. At the end of the procedure IOP was assessed by pressing the sclera away from the injection site with fingertip. If the IOP was felt very high then paracentesis was done at extreme temporal limbus. The patient was seated on the table and the patency of central retinal artery was confirmed with direct ophthalmoscope. The patient was advised to maintain the head posture in such a way that the gas bubble remains at the retinal break. Then the patients were shifted to their beds.

Postoperative Care: Every patient was examined on slit lamp on first postoperative day. The whole retina was examined. On next follow up after one week, first session of argon laser below the gas bubble was applied. Then on next follow up, two weeks after surgery, second session of laser was applied to encircle the retinal breaks. The patients were examined every month for six months.

RESULTS

Group A: In nine, out of ten, cases the retina was attached on the first postoperative day and remained attached on last follow up, 6 months after surgery. The success rate was 90%. In one case the retina remained detached.

Group B: The results were quite disappointing as compared to the group A. In only five, out of ten, cases retina was attached till the last follow up, six months after surgery. In other five patients retina was partially attached in early days but re-detached after gas bubble absorption.

Table 1: Pneumatic retinopathy

	No of Eyes (n=10)	Percentage
Pneumatic retinopathy with Cryo attached retina	9	90%
Pneumatic retinopathy without Cryo attached retina	5	50%

Table 2: Comparison of flat retina in both groups

Group	No. of Cases	Flat Retina	Success Rate
A	10	9	90%
B	10	5	50%
A+B	20	14	70%

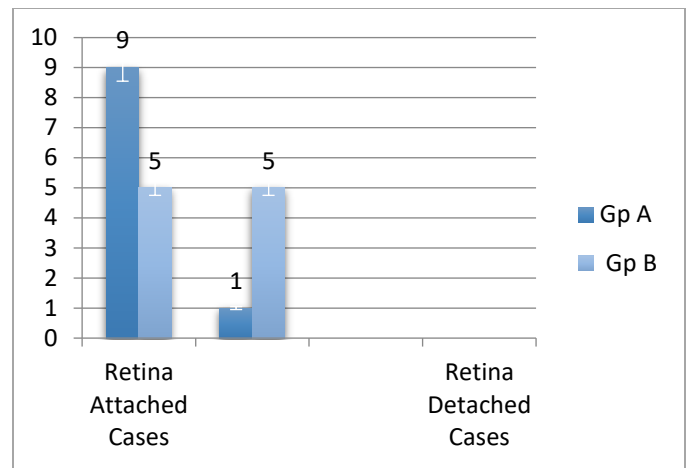


Figure 1: Comparison between two techniques of Pneumatic Retinopathy

Table 3: Suitability criteria of patients for PR

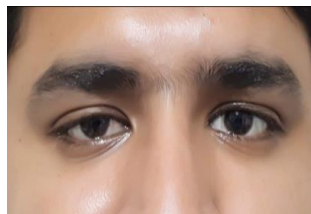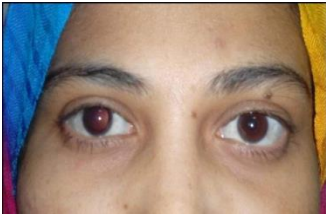
Suitable	Possible	Unsuitable
Single break in superior 8 clock hours	Recurrent RD after scleral buckling/PPV	Uncontrolled glaucoma
More than one break in superior half within one clock hour	Failed PR	PVR grade C or D
Phakic eye	Pseudophakic	Mature cataract
Patient able to maintain posture	Aphakic	Inferior 4 clock hour retinal breaks
	Mild lattice degeneration	Giant retinal tear
		Patient unable to maintain posture

IOP rise after Gas injection: This is a major challenge faced in this procedure but can be managed easily. In March 2018, Stephen & Wing reported that in 22 eyes undergoing SF6 gas injection during pneumatic retinopathy the recorded IOP was as follows:

Just after injection..... 97.2 mm Hg
 After a few minutes 46.5 mm Hg
 Within 30 to 60 minutes..... Baseline IOP

Once the IOP touched the baseline level, it never increased again. During the pressure spike it is essential to do paracentesis if central retinal artery pulsation is absent.

The unique beauty of PR: The most impressive aspect of this procedure is cosmetic look of the operated eye during postoperative period. Even on first postoperative day we did not find any sign of surgical trauma or inflammation in the operated eye. The operated and non-operated both eyes looked alike. This procedure can be done as outpatient procedure. There is less discomfort than operating room procedures. No need of general anesthesia. There is neither postoperative change in refractive error nor diplopia. It carries less risk of infection. It is a very low-cost procedure with faster ocular & systemic recovery. No need of highly advanced, costly equipment. In case of failure, operating room procedures are still possible without affecting prognosis.



DISCUSSION

Different studies described different success rate from 53-100 percent. The trend setting first report of Hilton & Grizzard³ described the success rate 90%. A review of 26 studies by Grizzard et al⁹ in 1995 reported an average success rate of 79%. In 1998, Lisle et al¹⁰ reported 83%. In 1999, Assi et al¹¹ described 61%. In 2000, Eter et al¹² reported 65% while Abecia et al¹³ reported 82%. In 2002, Kleimann et al¹⁴ found success rate 75%. In 2006, A A Zaidi et al¹⁵ published a report in British Journal of Ophthalmology and described success rate 54 % with single procedure and 66 % with additional steps. In 2011, Yee KM¹⁶ reported 85.7 % success rate. In 2018, Abhinav Dhani et al¹⁷ described 60 % success rate. In 2019, Emami et al¹⁸ described success rate 63.6% of surgeries done by Vitreoretinal fellows. From Pakistan, we could find only one report published in PJO 2015 by I Q Malik et al¹⁹. They described success rate 66%.

CONCLUSION

Pneumatic retinopexy is minimally invasive procedure and a good surgical option for treatment of fresh, superior primary rhegmatogenous retinal detachment in phakic eyes. Transconjunctival cryotherapy, before the gas injection, significantly improves the success rate of the pneumatic retinopexy.

REFERENCES

- Andrew W. Eller, MD The what, why, who and how of pneumatic retinopexy Ocular Surgery News U.S. Edition, December, 2014.
- Rosengren B. Results of treatment of detachment of the retina with diathermy and injection of air into the vitreous. Acta Ophthalmol. 1938;16(4):573-579.
- Hilton GF, Grizzard WS. Pneumatic retinopexy. A two-step outpatient operation without conjunctival incision. Ophthalmology. 1986;93(5):626-641.
- Norton EWD. Intraocular gas in the management of selected retinal detachments. Trans Am Acad Ophthalmol Otolaryngol. 1973;77(2):OP85-98.
- Vyngantas CM, Peyman GA, Daily MJ, Ericson ES. Octafluorocyclobutane and other gases for vitreous replacement. Arch Ophthalmol. 1973;90(3):235-6.
- Fineberg E, Machemer R, Sullivan P. SF6 for retinal detachment surgery; a preliminary report. Mod Probl Ophthalmol. 1974;12(0):173-6.
- Escoffery RF, OLK RJ, Grand MG, Boniuk I. Vitrectomy without scleral buckling for primary rhegmatogenous retinal detachment. Am J Ophthalmol. 1985;99(3):275-81.
- Ai E, Gardner TW. Current patterns of intraocular gas use in North America. Arch Ophthalmol. 1993;111(3):331-2.
- Grizzard W, Hilton GF, Hammer ME et al. Pneumatic retinopexy failures: cause, prevention, timing, and management. Ophthalmology. 1995;102(6):929-36.
- Lisle C, Mortensen K K, Sjolie A K. Pneumatic retinopexy. Acta Ophthalmol Scand 1998;76:486-490. [PubMed]
- Assi A C, Charteris D G, Pearson R V. et al Pneumatic retinopexy in the treatment of primary rhegmatogenous retinal detachment. Eye 1999;13:725-728. [PubMed]
- Eter N, Boker T, Spitznas M. Long-term results of pneumatic retinopexy. Arch Clin Exp Ophthalmol 2000;23:8677-681.
- Abecia E, Pinilla I, Oliván JM, Larrosa JM, Polo V, Honrubia FM. Anatomic results and complications in a long-term follow-up of pneumatic retinopexy cases. Retina. 2000;20(2):156-61.
- Kleinmann G, Rechtman E, Pollack A, Schechtman E, Bukelman A. Pneumatic retinopexy: results in eyes with classic vs relative indications. Arch Ophthalmol. 2002;120(11):1455-9.
- Zaidi AA, Alvarado R, Irvine A. Pneumatic retinopexy: success rate and complications. Br J Ophthalmol. 2006;90(4):427-8.
- Yee KM, Sebag J. Long-term results of office-based pneumatic retinopexy using pure air. Br J Ophthalmol. 2011;95(12):1728-30.
- Abhinav Dhani, Kunal Kaushik Shah, Dhanashree Ratra Pneumatic retinopexy outcomes as primary or secondary surgical option for treating rhegmatogenous retinal detachment: ijo, 2018;66(3):420-5.
- Emami-Naeini P, Vuong VS, Tran S, Morse LS, Moshiri A, Park SS, Yiu G. Outcomes Of Pneumatic Retinopexy Performed By Vitreoretinal Fellows. Retina. 2019 Jan;39(1):186-192.
- Irfan Qayyum Malik, Ch. Javed Iqbal, Yasir Afzal, nasir ch, tehseen mehmoed mahju, Pneumatic Retinopexy for Early, Rhegmatogenous Retinal Detachment, Pak J Ophthalmol. 2015;31(4):203-6.

AUTHORSHIP AND CONTRIBUTION DECLARATION

AUTHORS	Contribution to The Paper	Signatures
Dr. Muhammad Arif Associate Professor, Ophthalmology Department, FMU/Allied Hospital, Faisalabad	Patient Examination, Counseling and Surgical Procedures	
Dr. Qamar Mehboob Associate Professor, Physiology Department, Faisalabad Medical University, Faisalabad	Data Collection, Statistics and Paper Writing	
Dr. Muhammad Nawaz Malik Associate Professor, Ophthalmology Department, FMU/Allied Hospital, Faisalabad	Patient Examination and Cryotherapy	