

Penile Fracture

Zahid Iqbal, Muhammad Irfan Munir, Safdar Hassan Javed, Ghulam Mahboob Subhani

Penile fracture is a real urological emergency and underreported¹ due to the shyness to describe it therefore it leads to complications like erectile dysfunction later on. Penile fracture is defined as fracture of the tunica albuginea of corpus cavernosum of penis due to blunt trauma to erect penis.² Because it is a relatively rare emergency, our colleagues may not be knowing much of its details. The purpose of this review is to introduce this subject in a concise and simple manner so that problem may be identified early and get its prompt management done at some specialized center. Conservative management (delaying the management) may lead to devastating functional, physical and psychological complications.³ Penis is composed of two corporal bodies, corpora cavernosa are joined by a septum and a corpus spongiosum investing the urethra.⁴ Corpus cavernosum is surrounded by tunica albuginea containing sinusoids in it. These sinusoids fill with blood during erection. This blood comes through internal pudendal artery. Tunica albuginea is a layer which is 0.5 mm thick when stretched during erection and it is 2 mm thick when penis is flaccid. Both the corpora cavernosa are invested in Buck's fascia. Between the tunica albuginea and buck's fascia run the neuro-vascular bundle typically at 2 and 10 o'clock position. Outside the Buck's fascia is the layer of dartos fascia and outer to it is the skin. Dorsal to both corpora cavernosa runs the urethra invested in corpus spongiosum to exit through the external urethral meatus. Glans is the distal expansion of the corpus spongiosum. Proximally both the corpora cavernosa are attached with pubic bone and distally they end at glans penis. The loose skin of prepuce normally covers the glans of an uncircumcised patient.

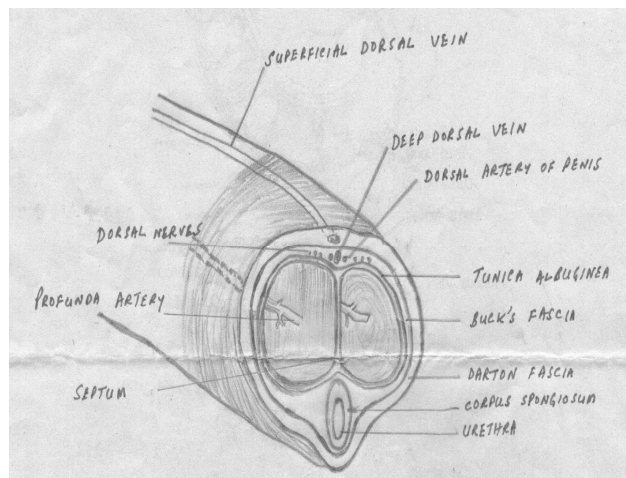


Figure 1: Anatomy of penis

The act of erection is a complex phenomenon involving the higher brain centers, which are stimulated by thought, vision or stimuli from external genital organs. After sexual stimulation there is outpouring of arterial blood into the sinusoids of corpora cavernosa leading to erection. The tunica albuginea thins out, stretches and impedes the venous return and tumescence is achieved. After ejaculation blood is poured out of corpora cavernosa and detumescence results. During erection if there is blunt trauma to penis tunica albuginea of corpus cavernosum is ruptured transversely and usually near its base.⁵ Blood leaks out of it and accumulates deep to Buck's fascia, which is usually palpable. The penis is bent away from the site of tear producing the typical S-shaped curve/deformity and ecchymosis and swelling at the site of tear is usually noted. Patients may hear a popping or cracking sound with rapid detumescence.⁶

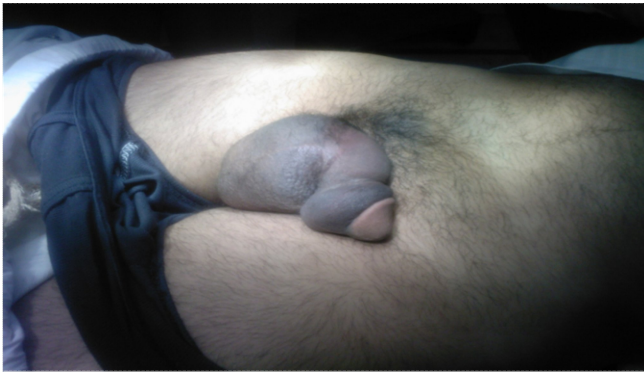

Fig.2: Typical S-shaped deformity in penile fracture

Cause of injury is blunt trauma to erect penis during sexual intercourse when erect penis misses the introitus and hits the pubic bone or perineum. It may happen during masturbation when erect penis is bent forcefully to achieve detumescence or rolling over erect penis in bed during nocturnal erections.^{7,8}

Symptoms are swelling of penis, deformity and ecchymosis over penile skin. Its signs are swelling of penis, ecchymosis, deformity and eggplant deformity and rarely the tunical defect may also be palpable. The injury may be associated with rupture of urethra when insult is more aggressive leading to rupture of both corpora cavernosa and partial rupture of urethra evident by blood at tip of penis, inability to pass urine or an inability to catheterize patient.⁹

It is diagnosed by typical history and clinical findings.¹⁰ Sophisticated tests like cavernosography and MRI are not usually required in cases of typical history and physical findings as they unnecessarily delay surgery.¹¹ Cavernosography involves the injection of contrast medium into the corporal body and it leaks from the site of fracture and latter may lead to fibrosis, similarly MRI is costly and not available everywhere. Ultrasound is a cheap modality, however rarely used to diagnose the fracture site.^{12,13} Retrograde urethrogram may be helpful in diagnosing the ruptured urethra.

There are two schools of thought regarding the management of penile fracture; One conservative management and second immediate surgical intervention. Conservative management includes anti-inflammatory drugs, ice packs, antibiotics and medicines to reduce penile erections like estrogens, antiandrogens, sedative medications and potassium bromide. This conservative approach is associated with

more complications like erectile dysfunction, deformity, fibrosis etc.^{4,14} Immediate surgical intervention is done after taking informed consent and doing baseline investigations to assess fitness for anesthesia. Either spinal anesthesia or general anesthesia is used. Exposure is achieved by different incisions; usually applied incision is subcoronal circumferential incision with degloving of penile skin. Second most commonly used incision^{15,16,17} is directly over the site of hematoma.¹⁸ Rarely incision may be inguinoscrotal especially in complicated injuries and injuries involving the root of penis.¹⁹ Subcoronal circumferential incision gives simultaneously adequate exposure for the repair of both the corpora and urethral tear. Complications of this incision include edema due to extensive dissection, slight decreased sensations due to trauma to nerves, subcoronal skin necrosis, infections and abscess formation.¹⁴ These are minor complications and this incision is most widely used for penile fracture. Incision over the haematoma gives minimal trauma to the penile skin with little edema but exposure is little and injury to contralateral corpus cavernosum cannot be repaired, similarly urethral repair may not be done through this incision. Exploration may be negative with no corporal tear and only dorsal vein tear but again exploration and evacuation of hematoma is recommended.¹⁵

Different suture materials are used to repair the tunical defect; non absorbable continuous suture with inverting knots or absorbable suture.

Patient usually remains admitted in ward for 48-72 hours and is managed with intravenous antibiotics, painkiller and sedatives to reduce penile erections. Severity of pain is one factor stopping the erections in postoperative period. Foley catheter is removed on day 3-5 or day 14 in cases of urethral tear. Patient is sent to home usually after 72 hours.

Complications may be early or late. In early complications bleeding, pain, penile edema, painful erections and wound sepsis are noted. Late complications include erectile dysfunction, chordee, fibrous plaque, there may be palpable knots of non absorbable suture material used to repair the tunical defect, stricture urethra or urethra-cutaneous fistula in cases of urethral tear.¹⁰ Erectile dysfunction is usually self limiting and resolves in 3-4 months, fibrous plaque is treated by its excision, stricture urethra is treated by internal urethrotomies with cold knife and palpable knots are treated by their removal under local anesthesia.

Mean age at presentation is different in different studies. A study conducted at Khyber teaching Hospital Peshawar showed age range of 30-40 years and a study by Mydlo JH, showed mean age of presentation to be 27 years.^{13,20} A study at hong kong showed mean age at presentation to be 43 years (4th decade).¹² Mode of injury is reported to be sexual intercourse in 83% cases by Kochakaren W et al while 73.7% cases were due to noncoital causes in a series by Ekwere and Al Rashid.^{6,21} A local study conducted at Urology department Allied Hospital Faisalabad showed that all the 13 patients of penile fracture were due to sexual intercourse (unpublished data).

Site of injury is to the base of penis and mostly to the right side in different series (Roohul Muqem, Asghari Mausi MK).^{5,13} Coincidence of associated urethral injuries and bilateral cavernosal injuries are mentioned to be 14.7% by Mydlo JH, Roohul Muqem and CH Chung.^{12,13,20}

Preferred incision to be employed is subcoronal circumferential incision with minimal complications and excellent results.^{13,22} Penile fracture may mimic dorsal vein tear and its incidence (incidence of negative exploration) range from 15% to >50%.¹⁵ Usual complications reported to be after surgical exproation are erectile dysfunction (from 16.6%, Nane I, 27%, Chung, 35% by Roohul Muqem).^{12,13,23} Mild penile deformity and urethral stricture, delayed chordee is seen in 30-53%(Kalash, Pryer).^{24,25}

REFERENCES

1. Bhuyian ZH, Khan SA, Tawhid MH, Islam MF. Personal series with clinical review of fracture penis. *Mymensingh Med J* 2007;16:187-90.
2. Orvis BR, McAninch JW. Penile rupture. *Urol Clin North Am* 1989; 16:369-375.
3. Muentener M, Suter S, Hauri D, Sulser T. Long term experience with surgical and conservative treatment of penile fracture. *J Urol* 2004;172:576-9.
4. Richard AS, Joshua AB. Penile fracture and trauma.[Online]. [Cited 2008 Oct 29]; Available from:URL:www.emedicine.com/med/topic3415.htm.
5. Asgari MA, Hossein SY, Safarinejad MR, Samadzadeh B, Bardideh AK. Penile fractures: evaluation, therapeutic approaching and long term results. *J Urol* 1996;155: 148-9.
6. Kochakarn W, Visechsindh V, Maungman V. Penile fracture; long term outcome of treatment. *J Med Assoc Thai* 2002;85:179-82.
7. Aman Z, Abdul Qayum, Khan M, Afridi V. Early surgical intervention in penile fracture. *J Postgrad Med Inst* 2004;18:432-8.
8. Gondal KM, Ali AA, Ranjha MA, Ijaz MJ, Shah TA. Management of penile fracture. *Ann KE Med Coll* 2001;7:47-9.
9. Derouiche A, Belhaj K, Hentati H, Hafsia G, Salama MR, Chebil M. Management of penile fractures complicated by urethral rupture. *Int J Impot Res* 2008 20: 111-4.
10. Eke N. Fracture of Penis. *Br J Surg* 2002; 89:555-65.
11. Fedel M, Venz S, Andreessen R, Sudhoff F, Loening SA. The value of magnetic resonance imaging in the diagnosis of suspected penile fracture with atypical clinical findings. *J Urol* 1996;155:1924-7.
12. Chung CH Szeto YK, Lai KK. Fracture of penis: a case series. *Hong Kong Med J* 2006;12:197-200.
13. Rooh-ul-Muqem, Jan Q, Zarin M. Management of penile fracture. *Pak J Med Sci* 2006;22:23-7.
14. Sawh S I, O'Leary M P, Ferreira MD, Berry AM, Maharaj D. Fracture penis: a review. *Int J Impot Res* 2008;20:366-9.
15. Bar-Yosef Y, Greenstein A, Beri A, Lidawi G, Matzkin H, Chen J. Dorsal vein injuries observed during penile exploration for suspected penile fracture. *J Sex Med* 2007;4(Pt 2):1142-6.
16. Zargooshi J. Penile fracture in Karmanshah, Iran: report of 172 cases. *J Urol* 2000;164:364-8.
17. Ghanem AN. Penile fracture in Kermanshah, Iran: the long term results of surgical treatment. *Br J Urol* 2003;91:301-2.
18. Naraynsingh V, Maharaj D, Kuruvilla T, Ramsewak R. Simple repair of fracture penis. *J R Coll Surg Edinb* 1998;43:97-8.
19. Seftel AD, Haas CA, Vafa A, Brown SL. Inguinal scrotal incision for penile fracture. *J Urol* 1998;159:182-4.
20. Mydlo JH. Surgeon experience with penile fracture. *J Urol* 2001; 166(2): 526-8.
21. Ekwere PD, Al-Rashid M. Trends in the incidence, clinical presentation and management of traumatic rupture of corpus spongiosum. *J Natl Med Assoc* 2004; 96:229-33.
22. Dincel C, Caskurlu T. Fracture of penis. *Eastern J Med* 1998;3:17-9.
23. Nane I, Tefekli A, Armangan A, Sanli O, Kadioglu A. Penile vascular abnormalities observed long-

-
- term after surgical repair of penile fracture. Int J Urol 2004;11:316-20.
24. Kalash SS, Young JD. Fracture of penis. 2 Controversy of surgical versus conservative treatment. Urology 1984; 21:21-4
25. Ryor JP, Hill JT, Packham DM. Penile injury with particular reference to injury to the erectile tissue. Br J Urol 1981; 53: 42.

AUTHORS

- **Prof. Dr. Zahid Iqbal**
Head of Urology and Renal Transplantation Department. PMC/Allied Hospital Faisalabad.
- **Dr. Muhammad Irfan Muneer**
Medical Officer Urology and Renal Transplantation Department. PMC/Allied Hospital Faisalabad.
- **Dr. Safder Hassan Javaid**
Associate Prof. Urology and Renal Transplantation Department. PMC/Allied Hospital Faisalabad.
- **Dr. Ghulam Mahboob Subhani**
Assistant Prof. Urology and Renal Transplantation Department. PMC/Allied Hospital Faisalabad.