

Outcome of Open Reduction and Intramedullary Kirschner-Wires Fixation for Fracture Shaft Radius Ulna in Children

Noor Akbar Sial, Muhammad Javaid Iqbal, Muhammad Kaleem Shaukat

Abstract

Background: There has been a trend toward operative management of pediatric Diaphyseal Forearm Fractures (DFFx). We studied our experience with surgical management of these injuries to assess outcome and complications.

Objective: The purpose of this study was to assess outcome and complications associated with open reduction and intramedullary Kirschner-wire fixation for fracture shaft radius ulna in children. **Design:** Prospective study. **Setting:** Orthopedic surgery departments of Independent Medical College, Punjab Medical College and University Medical College Faisalabad. **Study Period:** Between March 2009 and February 2011. **Method:** The study group included 32 boys and 12 girls aged 6-15 years with unstable displaced fractures shaft radius, ulna or both. Relevant history and x-rays of the forearm were taken. We followed the inclusion and exclusion criteria. All the cases were treated with open reduction and retrograde Kirchner wire

fixation. The cases were followed for at least 6 months. Patients were assessed functionally and radiologically and results were graded according to the system described by Price et al as excellent, good, fair and poor. **Results:** This prospective study was completed on 44 patients 32 were male and 12 were female. All fractures were united in acceptable alignment. At final assessment there were 30 (68.18%) excellent, 8 (18.18%) good, 3 (06.82%) fair and 3 (06.82%) poor results. The fair or poor clinical outcome was higher in children above 10 years of age. Delayed union after IM intramedullary fixation occurred in 3 children over 10 years of age. **Conclusion:** This technique can provide precise fracture reduction, maintains stabilization for fracture healing, results in minimal cosmetic deformity, cost effective and facilitates easy removal of implants after treatment. **Key Words:** Forearm fractures shafts, Open reduction, Retrograde K-wiring, intramedullary fixation.

INTRODUCTION

Diaphyseal forearm fractures are common injuries among children, comprising 3-6% of all pediatric fractures¹. Undisplaced fractures can be safely treated in cast. In this study treat most closed fractures of forearm in children with conservative methods. However some fractures redisplace. Union is rarely a problem in displaced fractures. It is the residual deformity especially rotational or dysfunction in spite of remodeling². The remodeling capacity depends on the age, the site of fracture, the direction of angulation and its magnitude. There has been a rising trend towards surgical management for a larger percentage of diaphyseal forearm fractures. This trend has largely

been driven by technologic advances, sociologic changes, liability concerns, and perhaps even medical economics. Intramedullary (IM) fixation of pediatric forearm fractures has been rapidly adopted as a "minimally invasive" treatment compared with plate fixation (the standard mode of therapy for similar adult fractures). This procedure is less time consuming and easier metal work removal. Good functional, radiographic and cosmetic results have been reported in several series, leading to widespread enthusiasm of IM fixation³. Intramedullary fixation can be performed using a variety of implants such as K-wires, Rush pins, Steinman pins or flexible nails (Titanium

elastic nails) and forearm interlocking intramedullary nail⁴. We and others, however, have observed some short-comings of IM fixation, including delayed union⁵. This study evaluated treatment outcomes after open reduction and intramedullary K-wire fixation for diaphyseal forearm fractures.

MATERIAL AND METHODS

In this study 54 consecutive patients with severely displaced and unstable diaphyseal forearm fractures were selected from orthopedic surgery departments of Independent Medical College, Punjab Medical College and University Medical College Faisalabad between March 2009 and February 2011. 4 patients declined surgical treatment in spite of severely displaced fractures. 50 patients were operated at the beginning or after redisplacement that occurred during the conservative treatment of cast immobilization or after applying wooden sticks by bone setters. We followed the inclusion and exclusion criteria. Six of these patients (4 male and 2 female) were lost during follow-up before union and therefore excluded from this study. 44 out of 50 were available for follow up. Relevant history and x-rays of the forearm were taken. A comprehensive data was collected of all patients with diaphyseal forearm fractures to obtain the following information: patient age, sex, date of injury, fracture status (open vs. closed), fracture location (proximal 1/3 vs. middle 1/3 vs. distal 1/3), fracture pattern (transverse or oblique), bone involved (both radius and ulna or radius only or ulna only), date of surgery, time to radiographic union, final range of motion (supination and pronation), pain, return of good function, deformity and postoperative complications. The informed consent for surgery was obtained after the approval of study from ethical review committee Punjab Medical College.

INCLUSION CRITERIA

- Simple unilateral fractures of forearm bones
- Open fractures
- Unacceptable alignment following attempts at closed reduction
- Nonunion

- Refracture of previously treated fracture
- Unstable displaced fractures shaft of radius, ulna or both

EXCLUSION CRITERIA

- Elbow or wrist fracture at the junction of the diaphysis and metaphysis.
- Pathologic fracture secondary to tumor or bone metabolic disease,
- Associated radial head fracture, Monteggia and Galeazzi fractures
- Associated visceral injuries

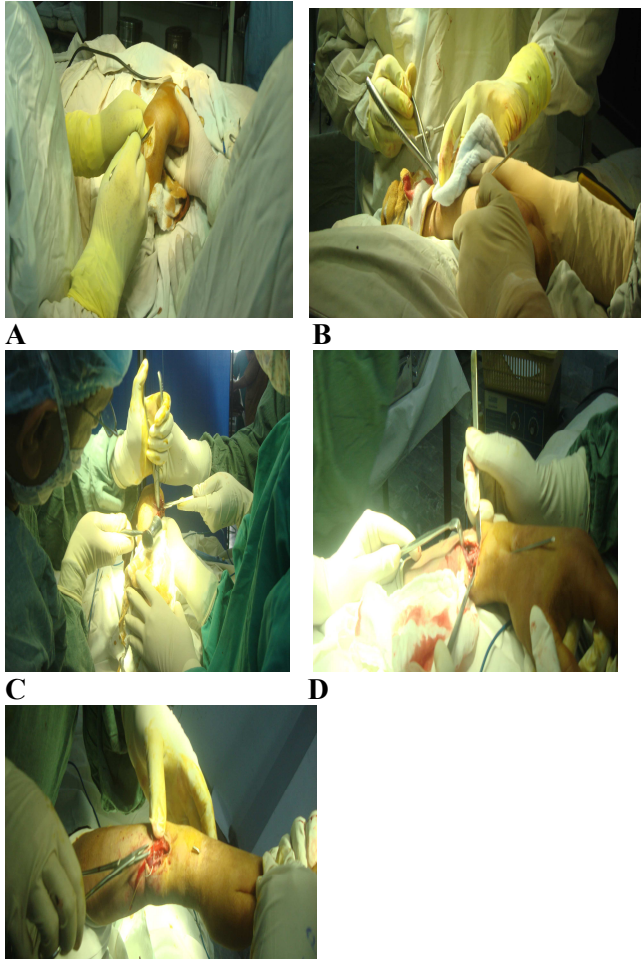
SURGICAL TECHNIQUE

After taking all necessary pre-operative measures under general anaesthesia and tourniquet control the radius was exposed through 1st small dorsal incision. A Kirschner wire of appropriate thickness was driven distally with wrist flexed and in ulnar deviation so that the wire exited on the dorsolateral side of distal end of the radius. The wire was flushed to the proximal end of the distal segment. Similarly 2nd mini incision was given over the ulna. Fracture was exposed with the help of spikes and bone holders and K-wire of appropriate size was inserted through fracture end into the ulna proximally keeping the elbow in flexion so the wire should exit through the tip of olecranon. The wire was flushed with the distal end of the proximal segment. This is the easy way of K-wire insertion without damaging soft tissues rather completing one by one as in individual bone fracture. After the insertion of k-wires in one segment of each bone 1st the radius was reduced and the radial wire was driven up to radial head. Similarly ulna was reduced and ulnar wire was driven distally down to the styloid process. Single-bone fixation is technically easier and involves less operating time. After checking the stability both wires were bent with wire bender. Tourniquet was removed, haemostasis secured and both wounds were closed. Above elbow POP applied, windows were made for wound care. Dressing was changed on 1st post operative day. POP was removed after 3 to 5 weeks. The K-wires were removed after healing of the fractures. Patients were followed every month for clinical and radiological assessment and for any

complications. The range of movements was recorded for wrist elbow and forearm. The cases were followed up for 6 months. At the final follow-up, clinical outcomes were graded according to the system described by Price et al. (Table 1)⁶.

Figure-1

A Small Dorsal incision. B Wrist in flexion, K-wire in distal segment of radius C. Flushing of K-wire D. After reduction K-wire pushed into proximal segment D. closure of wound after bending distal end of K-wire.



F

Table-1
Grading system of Price et al

| Outcome | Symptoms | Loss of Forearm Rotation |
|-----------|---------------------------------------|--------------------------|
| Excellent | No complaints with strenuous activity | <15° |
| Good | Mild complaints | 15°-30° |

| | | |
|------|---------------------------------------|---------|
| | with strenuous activity | |
| Fair | Mild complaints with daily activities | 31°-90° |
| Poor | All other results | >90° |

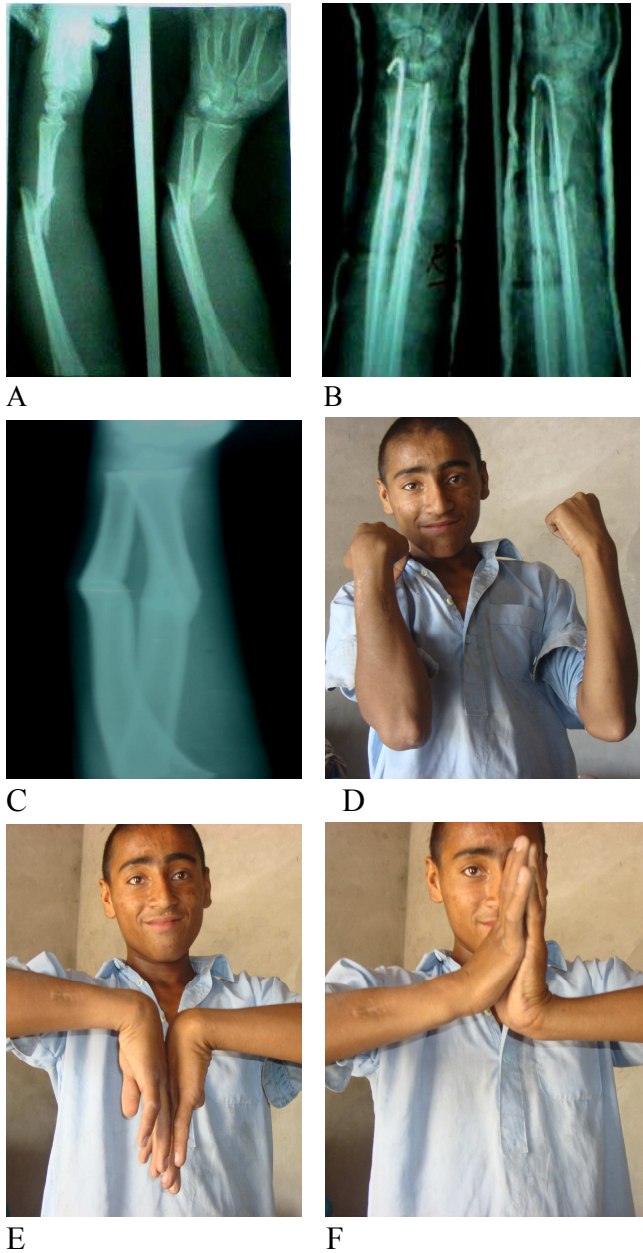
RESULTS

44 cases were completed for final evaluation. 32 patients were boys and twelve were girls, Male to female ratio was 2.7:1. The average age of patients treated with IM fixation was 12 years (range: 6 to 15 y). Right side was involved in 31 (70.45%) cases and left side in 13 (29.55%). Fracture in 34 (77.28%) was due to fall and sports activities, 5 (11.36%) by road traffic accident, 2 (04.54%) due to physical assault and 3 (06.82%) due to miscellaneous causes. In most cases the middle third was involved. The average time of surgery was 45 minutes (range 35-65 minutes). The mean follow-up was 6 months (range: 1 to 24 months). The mean time to fracture union was 8.6 weeks (range: 4 to 12 wk). 4 patients had superficial wound infection which resolved with dressing and antibiotics. 12 patients had problems of skin irritation with impingement of K-wires at exit points mostly at distal end of radius. 4 patients had transient weakness of thumb extensors. All patients regained a full range of elbow movement, except in two who had limited supination and pronation (<20°) due to a degree of malrotation. There was no intra-operative complication. Open fractures treated secondary to injury took longer time to heal as compose those that were opened surgically. There was a slight to, trend toward longer times to union in older patients. Delayed union in three cases was in patients older than 10 years of age treated with IM fixation. Two of these patients required reoperation and union was achieved with compression plate fixation. There were no cases of delayed union in patients younger than 10 years of age. There was no incidence of compartment syndrome, laceration or rupture of tendons and refracture after removal of k-wires. No evidence of epiphyseal growth arrest. The latest follow-up functional end results were 30 (68.18%) excellent, 8 (18.18%) good, 3 (06.82%) fair and 3 (06.82%) poor results. The fair or poor clinical outcome was higher in children above 10 years of age.

Table-2
Outcome of intramedullary K-wire fixation

| Outcome | Number | Percentage |
|-----------|--------|------------|
| Excellent | 30 | 68.18% |
| Good | 08 | 18.18% |
| Fair | 03 | 06.82% |
| Poor | 03 | 06.82% |

Figure-2
A pre-operative x-rays B. intramedullary fixation C. after healing and D, E, F excellent functional outcome.



DISCUSSION

With a greater ability to remodel, closed reduction and casting is the treatment of choice for pediatric diaphyseal forearm fractures⁷. Over the last decade, there has been a strong trend toward the increased use of internal fixation for pediatric and adolescent diaphyseal forearm as the results are generally excellent compared to traditionally treated by closed reduction and casting⁸. Some fractures are unstable or redisplacement occurs in cast, in these situations surgical fixation either with closed or open methods is beneficial to avoid repeat reductions, additional corrective surgical procedures, and functional limitations⁹. A cadaveric study by Tarr et al demonstrated that fracture angulation between 5 and 10 degrees at the midshaft of the forearm can lead to pronation deficits of 10% to 83% of normal and supination deficits of 5% to 27% of normal¹⁰. Surgical treatment is deemed necessary when malalignment is >15°, in order to avoid poor functional outcomes. The close fixation is done under image intensifier when facilities are available and more experience in technique is required¹¹. The drawback of close IM nailing is multiple passes which causes increased soft tissue injury or a satisfactory reduction could not be obtained to pass the nail. The most common cause of conversion to open reduction is soft-tissue interposition¹². The external fixator is a good treatment for open, comminuted or special distal diaphyseal fractures in older children and adolescents. Open reduction facilitates accurate IM fixation and is much less traumatic to the fracture site than multiple reduction maneuvers¹³. Open reduction and compression plate fixation is invasive. The complication rates are high in plating and there are added risks related to the removal of the plates. Compared with plating IM nailing is considered to be much less invasive and easy driven or removal of wires¹⁴. Our results are comparable to other investigators. Ogonda et al had only one delayed union and one nonunion of ulna in his series¹⁵. Seyfettinoglu et al in 2009 reported 82% excellent surgical results comparable to this study of 86% excellent to good¹⁶. Mostafa et al in 2009 reported male to female ratio of 2.2:1 in their study on thirty two children¹⁷ while in our study male to female ratio is 2.7:1. Kose and Deniz in 2008 concluded that intramedullary Kirschner wiring is a better option than plating in forearm fractures¹⁸. Celebi L in 2007 concluded that

intramedullary fixation is safe, inexpensive with excellent anatomic and functional results in children who developed redisplacement with cast treatment¹⁹. We conducted this study with a limited follow-up period (mean was 6 months); however, in the treatment of pediatric fractures, extended follow-up is not typical. Following an international trend toward more aggressive management of pediatric fractures, orthopaedic surgeons have rapidly adopted IM nailing of pediatric diaphyseal forearm fractures as a “less invasive” procedure with low complication rate, relative to standard plating²⁰. Although there was no control group for comparison, intramedullary K-wires fixation can have a role for forearm fractures in children after failed conservative treatment. There were some difficulties like illiteracy, surgical treatment phobia poor socioeconomic conditions and irregular follow up while conducting the study.

CONCLUSION

Which technique can provide precise fracture reduction, maintains stabilization for fracture healing, results in minimal cosmetic deformity, and facilitates easy removal of implants after treatment.

REFERENCES

1. Schmittenbecher PP. State-of-the-art treatment of forearm shaft fractures. *Injury* 2005; 36:25-34.
2. Bhattia M, Housden PH. Redisplacement of Paediatric Forearm Fractures. Role of plaster moulding and padding. *Injury* 2006; 37:259-68.
3. John M. Flynn MD, Kristofer J. Jones MD, Matthew R. Garner BS, and Jennifer Goebel BA. Eleven Years Experience in the Operative Management of Pediatric Forearm Fractures. *Pediatr Orthop.* 2010; 30:313-19.
4. Az-Gao H, et al. Internal fixation of diaphyseal fractures of the forearm by interlocking intramedullary nail: short-term results in eighteen patients. *J Orthop Trauma* 2005; 19:384-91.
5. Schmittenbecher PP, Peter P, Fitze G, et al. Delayed healing of forearm shaft fractures in children after intramedullary nailing. *J Pediatr Orthop* 2008; 28:303–306
6. Price CT, Scott DS, Kurzner ME, Flynn JC. Malunited forearm fractures in children. *J Pediatr Orthop* 1990; 10:705–12.
7. Zions LE, Zalavras CG, Gerhardt MB. Closed treatment of displaced diaphyseal both-bone forearm fractures in older children and adolescents. *J Pediatr Orthop.* 2005; 25:507–511.
8. Bukhari SAH. Comparison of image assisted Percutaneous intramedullary Kirschner wire stenting with closed Reduction for fractures of radius and ulna in children. *Journal of Surgery Pakistan* 2010; 15:78-81.
9. Ahmed I, Askar Z, Durani Z et al. K-wire fixation of Radius-Ulna Fractures. *Pakistan Journal of Surgery* Volume23, Issue3, 2007:208-11.
10. Tarr R, Garfinkel A, Sarmiento A. The effects of angular and rotational deformities of both bones of the forearm. An in vitro study. *J Bone Joint Surg* 1984;66:65–70
11. Kose N, Gokturk E, Turgut A, Seber S, Guanali I. Percutaneous reduction of irreducible Forearm Fractures in children. *Orthopaedics* 2006; 29:584-6.
12. Lascombes P, Haumont T, Journeau P. Use and abuse of flexible intramedullary nailing in children and adolescents. *J Pediatr Orthop* 2006; 26:827–834.
13. Kucukkaya M, Kabukcuoglu Y, Tezer M, Eren T, Kuzgun U. The application of open intramedullary fixation in the treatment of pediatric radial and ulnar shaft fractures. *J Orthop Trauma.* 2002; 16:340-4.
14. Garg NK, Ballal MS, Malek IA, et al. Use of elastic stable intramedullary nailing for treating unstable forearm fractures in children. *J Trauma.* 2008; 65:109–115.
15. Ogonda L, Chong W, Wray R, Canavan B. Delayed union and nonunion of the Ulna following intramedullary nailing in children. *J Pediatr Ortho* 2004; 13:330-3.
16. Seyfettinolu F, Duygun F, Kovalak E, Ersan O, Ates B, Ates Y. Assessment of surgical and conservative treatment of forearm fractures: results in juveniles. *Ulus Travma Acil Cerrahi Derg* 2009; 15:371-76.
17. Mostafa MF, EL-Adl G, Enan A. Percutaneous Kirschner-wire fixation for displaced distal forearm fractures in children. *Acta Orthop Belg* 2009;75:459-66.
18. Kose O, Deniz G, Yanik S, Gungor M, Islam NC. Open intramedullary Kirschner wire versus

screw and plate fixation for unstable forearm fractures in children. J Orthop Surg 2008; 16:165-169.

19. Celebi L, Muratli HH, Do an O, Ya murlu MF, Aksahin E, Bicimo lu A. The results of intramedullary nailing in children who developed redisplacement during cast treatment of both-bone forearm fractures. Acta Orthop Traumatol Turc 2007;41:175-182.
20. Ali AM, Abdelaziz M, Lakanney MRE. Intramedullary nailing for diaphyseal forearm fractures in children after failed conservative treatment. Journal of Orthopaedic Surgery 2010; 18:328-31.

Footnotes

Source of Support: No benefits in any form have been received or will be received from a commercial party related directly or indirectly to the subject of this article.

Conflict of Interest: None

AUTHORS

- **Dr. Noor Akbar Sial**
Assistant Professor Orthopaedic
Independent Medical College, Faisalabad
- **Dr. Muhammad Javaid Iqbal**
Assistant Professor Orthopaedic
Punjab Medical College, Faisalabad
- **Dr. Muhammad Kaleem Shaukat**
Assistant Professor Orthopaedic
University Medical College, Faisalabad

Address for Correspondence

Dr. Noor Akbar Sial FCPS

Associate Professor Orthopaedic Independent Medical
College Faisalabad

dr_noor_akbar@hotmail.com www.sialortho.com