

Distal Urethral Stent: A Patient Friendly Approach after Repair of Hypospadias

Zahid Mahmood Nagra, Tamsil Ahsan Shafaat, Abdul Ghafoor

Abstract

In this case report we present a case of surgical repair of hypospadias followed by stenting of only distal part of urethra. The purpose of this report is to discuss the effectiveness of stenting

of only distal urethra leading to better post operative outcome and better patient compliance without any complication. **Key words:** urethral stent, hypospadias, external urethral sphincter

INTRODUCTION

Urethral stents are mandatory after any surgical procedure in urethra like repair of hypospadias, urethral stenosis and strictures. The duration of urethral stenting after tubularized incised plate (TIP) varies among surgeons. Typically the catheter is left for up to 7 days with the goal of minimizing post operative complications. Furthermore catheter induced stricture have been evaluated and experimental¹ and clinical studies demonstrated that latex catheter were more toxic than non-latex catheter². A thorough review of literature revealed an absence of papers specifically focused on length of urethral catheter or stent. Alternatives to indwelling urethral catheterization should be considered when appropriate³. Post operative comfort is a major issue after distal hypospadias repair and depends on adequate analgesia and unimpaired micturition, especially when no suprapubic catheter is in place⁴.

Corresponding Author:

Dr. Tamsil Ahsan Shafaat

Medical officer

Dept. of Plastic Surgery and Burns

PMC / Allied Hospital, Faisalabad

Tel. +0333-6630234

E-mail: tamsil_ahsan@hotmail.com

PROCEDURE

Various surgical techniques have been described for hypospadias repair. For many years meatal advancement and glanuloplasty (MAGPI) is among the mainstays of distal hypospadias repair.⁵ Urethral injury due to trauma can result from misjudged application of pressure during catheter insertion or from inflation of the balloon while still in the urethra⁶. The type and timing of urinary diversion after hypospadias repair has been a continuous source of debate with spectrum variation from suprapubic tube placement to stent-free procedure⁵. Usually a catheter is passed through the whole urethra, while in a few cases supra-pubic diversion is done along with urethral stenting. These procedures are associated with complications like pain, bladder spasm and infection, which have to be treated by anti-cholinergic medicines.¹ In our case we stented only distal portion of urethra i.e., distal to external sphincter, this stent just acted like a “splint” leading to a better re-epithelialization of incised plate and had a good post operative recovery and comfortable self control of urination by the patient.

DISCUSSION

This case report describes a patient friendly and comfortable approach towards postoperative care

and mobilization with full benefits of procedure. A 12 years boy who was operated for meatal advancement and glanuloplasty (MAGPI), and post operative stenting of urethra and meatus with a small piece of drain which stented only the anterior part of urethra distal to external urethral sphincter (figure. 1 & 2). With this modality patient can move freely without hazards of Foley/drain dislodgement and hanging of urine bag at bed side or carrying it in hand while walking. In this case patient recovered and tolerated the procedure well, having full voluntary urine control with him. He continued his urine habits as per his urge, while rest of wound dressing was done as usual. That stent was removed at 14th postop. day and patient showed full wound healing and uneventful recovery. (Figure.3)

TIP urethroplasty is widely accepted procedure for its better cosmetic results than other procedures. Duration of catheterization in TIP is associated with complications like urethral injury, stenosis and obstructive flow pattern⁷. These days TIP urethroplasty is preferred in cases of distal and mid-shaft hypospadias⁸. In all data available in internet different comparisons have been made between surgical techniques like TIP & TVIF, or comparison of duration of catheter placement but very rare data was found regarding the size of catheter/stent.

Figure-1
Patient In Standing Position with Stent and Dressing in Place

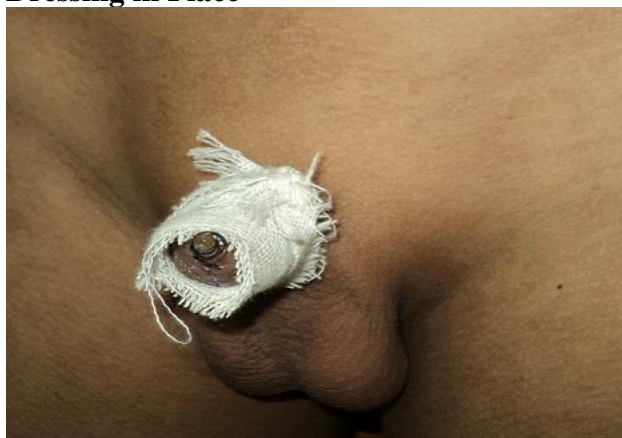

Figure-2
14th Post Op Day

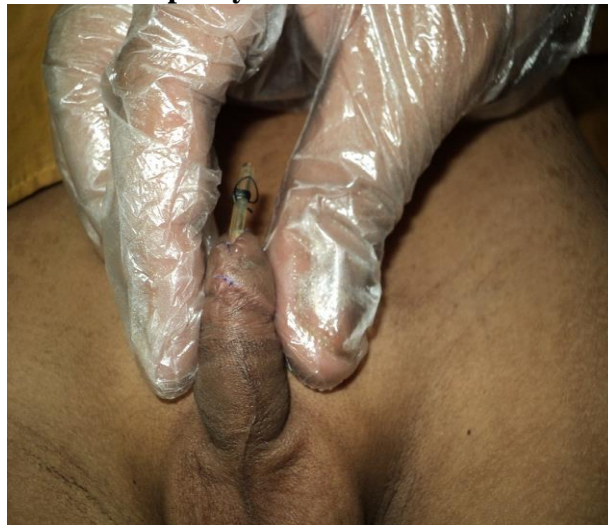
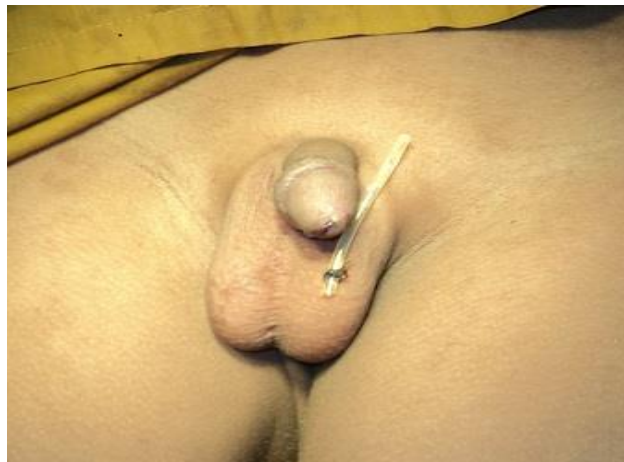
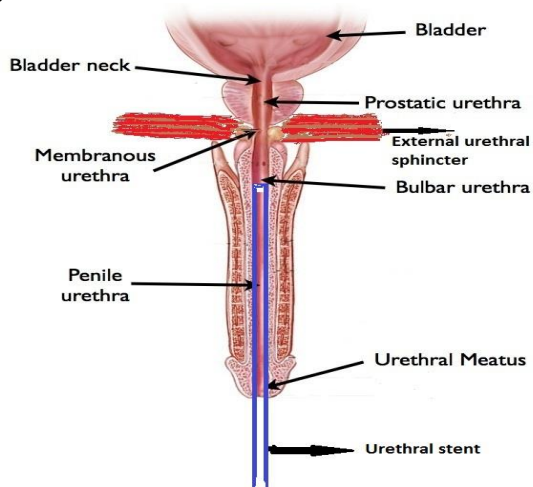
Figure-3
Size of Stent



This case points to a technique with better patient recovery and mobilization with proper control of micturition in comfortable surroundings with lesser disturbance of bladder tone and neurogenic involvement of sphincters. No signs of infection were observed after removal of stent while patient continued his urine habits as usual. A recent study on post operative care after hypospadias repair shows that parents of patients who have no or short dressing are less likely to contact the surgeon due to anxiety¹.

Drain was placed just for stenting of procedure site and remained distal to the external urethral sphincter as shown in Figure 4.

Figure-4
Diagrammatic Illustration of the Procedure



Studies have shown that in toilet trained children, the full urethral stent can lead to bladder spasm and discomfort requiring therapy with anti-cholinergic medications². In short, urethral stents without passing into the bladder can do well so in this matter further research should be continued. We hope to get further experience in this technique for improvement and adjustments.

REFERENCES

1. Ritch CR, Murphy AM, Woldu SL, Reiley EA, Hensle TW. Overnight urethral stenting after tubularized incised plate urethroplasty for distal hypospadias. *Pediatr Surg Int.* 2010; 26: 639-42.
2. Yec DS, Gelman J, Skarecky DW, Ahlering TE. Larger urethral catheter size leads to fossa navicularis stricture formation in robotic radical prostatectomy. *J Rebotic Surg.* 2007; 1: 151-4.
3. Gould CV, Umscheid CA, Agarwal RK, Kuntz G, Pegus DA; healthcare Infection Control Practices Advisory Committee. Guidelines for prevention of catheter associated urinary tract infection 2009. *Infec Control Hops Epidemiol.* 2010; 31: 319-26.

4. Metzelder ML, Kucbler JF, Glueer S, Suempelmann R, Ure BM, Petersen C. Penile block is associated with less urinary retention than caudal anesthesia in distal hypospadias repair in children. *World J Urol.* 2010; 28: 87-91.
5. Aslan AR, Yuccbas E, Tekin A, Sengor F, Kogan BA. Short term catheterization after TIP repair in distal hypospadias: who are the best candidates? *Pediatr Surg Int.* 2007; 23: 265-9.
6. Manalo M Jr, Lapitan MGM, Bukley BS. Medical interns' knowledge and training regarding urethral catheter insertion and insertion-related urethral injury in male patients. *BMC Med Edu.* 2011; 11:73.
7. Scarpa MG, Castagnetti M, Berrettini A, Rigamonti W, Musil. Urinary function fter Snodgrass od distal hypospadias: comparison with the Mathieu repair. *Pediatr Surg Int.* 2010; 26: 519-22.
8. Xu N, Yue XY, Li XD, Wei Y, Zheng QS, Jiang T, etal. Comparative outcomes of the tubularized incised plate and transverse islan flap onlay techniques for the repair of proximal hypospadias. *Int Urol Nephrol.* 2013; Sep 24 [E pub ahead of print].

AUTHORS

- **Dr. Zahid Mahmood Nagra**
Associate Professor
Dept. of Plastic Surgery and Burns
PMC / Allied Hospital, Faisalabad
- **Dr. Tamsil Ahsan Shafaat**
Medical Officer
Dept. of Plastic surgery and Burns
Allied Hospital, Faisalabad
- **Dr. Abdul Ghafoor**
Senior Registrar
Dept. of Plastic Surgery and Burns
Allied Hospital, Faisalabad

Submitted for Publication:	16-01-2014
Accepted for Publication:	29-01-2014
After minor revisions	