

Outcome of Dynamic Compression Plating in Fracture Shaft of Humerus

Muhammad Nadeem Yousaf, Shahab ud Din, Muhammad Rizwan Akram, Ajmal Yasin, Rana Dawood Ahmad Khan

ABSTRACT

Background: Fracture shaft of humerus is a common orthopedic problem and represents roughly 3% of all fractures, usually managed non-operatively. The usual operative modalities used for fixation of humerus fractures are the kuntscher nails, dynamic compression plate (DCP), external fixator and intramedullary nail (IMN). Plating of fracture shaft of humerus is the more common surgical treatment option. There is a higher rate of excellent and good results and tendency for earlier union with the plating of fracture shaft of humerus. **Methods:** This study was conducted at Orthopedic Department of Allied and DHQ Hospital Faisalabad from November 2011 to November 2012. All patients with fracture shaft of humerus were included and treated with dynamic compression plating. **Results:** 91 patients with mean age of 37.24 including 70

(76.9%) males and 21 (23.1%) females falling in inclusion criteria were operated by same orthopaedic surgeons team with same implant i.e. DCP. At 1ST postoperative day, 87 patients (95.60%) had no neurological deficit while 4 patients (4.40%) had neurological deficit. At 12th postoperative day only 9 patients (9.9%) had superficial wound infection while 82 patients (90.1%) have no wound infection. **Conclusion:** Humeral shaft fracture is one of the commonest fractures among the working community and elderly. Fixation of fracture with Dynamic Compression Plate is the treatment of choice. Postoperative radial nerve injury is an important complication and few patients in this study developed neurological deficit. **Keywords:** Fracture shaft of humerus, Dynamic Compression Plate (DCP), intramedullary nail humerus (IMN). Radial Nerve.

INTRODUCTION

Fracture shaft of humerus is a common orthopedic problem and represents roughly 3% of all fractures, usually managed non-operatively. In the earliest surgical texts dating back to 1600 BC, reduction maneuvers were discussed using traction, followed by bandaging with linen and other conservative measures.¹ Non-operative methods include skeletal traction, abduction casting and splinting, Velpeau dressing, hanging arm cast and functional bracing.²

Corresponding Author:

Dr. Muhammad Nadeem Yousaf
Department of Orthopedics
Allied Hospital, Faisalabad
Tel. +92 321-6604375
E-mail: drnadeem200@yahoo.com

Operative treatment is indicated in specific circumstances including open fractures, associated neurovascular injury, proximal and distal articular extension, patients with multiple injuries or polytrauma, floating elbow, progressive radial nerve deficits, significant soft tissue injury (unable to brace), pathologic fractures and failed non-operative management.^{3,4}

The usual operative modalities used for fixation of humerus fractures are the inlay and onlay tibial grafts, cerclage wires, kuntscher nails, dynamic compression plate (DCP), external fixator and intramedullary nail (IMN).⁵ Postoperative complications reported for DCP fixation are infection 20.8%⁶ and radial nerve injury 13.33%.⁵ Plating of fracture shaft of humerus is the more common surgical treatment option. Literature suggests plating as primary surgical treatment for

fracture shaft of humerus except in some open fractures requiring temporary external fixation, pathological fractures and large segmental fractures.⁷ There is a higher rate of excellent and good results and tendency for earlier union with the plating of fracture shaft of humerus.⁸ The treatment for humeral shaft fracture is still controversial, especially for complex fractures. Minimally invasive plate osteosynthesis is safe alternative way to classic surgical methods in the treatment of complex humeral shaft fractures, which had a high rate of union and less risk of complications.⁹ Objective of this study was to determine the outcome of Dynamic Compression Plating in fracture shaft of humerus in terms of wound infection and radial nerve injury.

MATERIAL & METHODS

This study was conducted at Orthopedic Department of Allied and DHQ Hospital Faisalabad from November 2011 to November 2012. All the patients with following common properties were included in the study.

- Patients of both genders and age group >12 and <70 yrs.
- Patients with type 1 open fractures (Gustilo Anderson classification).
- Early failure of conservative treatment presenting in Allied & DHQ Hospitals Faisalabad.
- Skeletally mature adults.
Patients with following properties were excluded from the study.
- Patients with type 2 & 3 open fractures.
- Patients with pathological fracture.
- Patients not fit because of head injury.

The fracture site was exposed through anterolateral approach. Radial nerve was identified and handled carefully. AO DCP was used, with the length depending upon the type of fracture. After reduction and fixation of fracture drain was placed. Wound was closed in layers. Postoperative check X-ray was done from same hospital radiology department and was elaborated

by senior registrar of orthopedic department. Patient was examined for neurological deficit on 1st postoperative day. Drain out on 2nd postoperative day. Patients were followed on OPD basis. Wound was checked on 12th postoperative day for infection. All the collected data were entered and analyzed on SPSS 16. Descriptive statistics was calculated for all the variables. Mean and standard deviation were calculated for quantitative variables like age. Frequency and percentages were calculated for all qualitative variables like sex, radial nerve injury and wound infection.

RESULTS

There were a total of 91 cases falling in the inclusion criteria. These were operated by same surgeons with same implant i.e. DCP. Mean age was 37.24.

Youngest patient was 22 years old while oldest one was 60 years of age (Table 1).

There were 70 (76.9%) males and 21 (23.1%) females (Table 2). Humeral shaft fractures encountered in this study were described according to their respective geometry of fracture (Table 3).

Results obtained in terms of geometry of fracture were as follows;

- Simple transverse fractures 56(61.54%).
- Spiral fractures 21(23.08%).
- Oblique fractures 14(15.38%).

Outcome of the patients was based upon post-operative radial nerve injury on 1st postoperative day and wound infection on 12th postoperative day. Results obtained were as follows;

Radial nerve injury on 1st postoperative day (Table 4)

- 87 patients (95.60%) had no neurological deficit.
 - 4 patients (4.40%) had neurological deficit.
- Wound infection on 12th postoperative day (Table 5)
- 82 patients (90.1%) have no wound infection.
 - 9 patients (9.9%) had superficial wound infection.
- No patients died during follow up. So mortality up to 12th postoperative day was 0 %.

Table 1: Age distribution

	N	Minimum	Maximum	Mean	Std. Deviation
Age	91	22.00	60.00	37.24	7.37

Table 2: Gender distribution

	Frequency	Percent
Male	70	76.9
Female	21	23.1
Total	91	100.00

Table 3: Geometry of fracture distribution

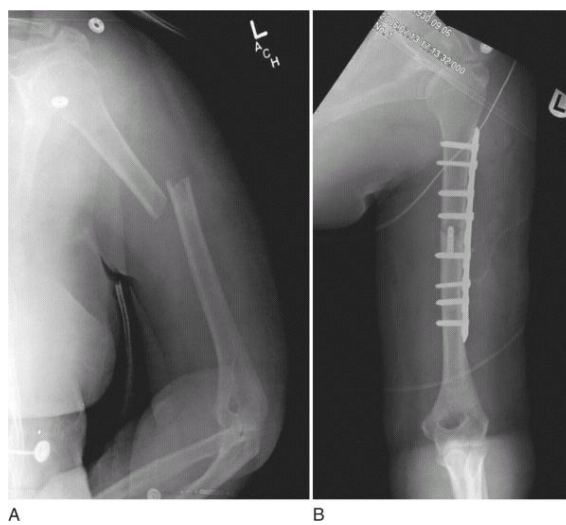
	Frequency	Percent
Simple transverse fractures	56	61.54
Spiral fractures	21	23.08
Oblique fractures	14	15.38
Total	91	100.00

Table 4: Radial nerve injury on 1st postoperative day

	Frequency	Percent
No neurological deficit	87	95.60
Neurological deficit	4	4.40
Death	0	0
Total	91	100.00

Table 5: Wound Infection On 12th Postoperative Day

	Frequency	Percent
No superficial wound infection	82	90.1
Superficial wound infection	9	9.9
Death	0	0
Total	91	100.00

**Fig: Fracture Shaft of Humerus Managed by DCP****DISCUSSION**

The indications for surgical management and internal fixation of fracture of the shaft of humerus are clear.^{2,10} Compression plating has been regarded as gold standard for operative treatment¹¹ with high rates of fracture healing and consolidation^{10, 12} and good outcome¹⁰ with no adverse effect of immediate full weight bearing on fracture union or alignment.

In this particular study the most important complication of radial nerve injury was evaluated after fixing fracture shaft of humerus with dynamic compression plate. Postoperative superficial wound infection was also assessed. 91 patients with mean age of 37.24 including 70

(76.9%) males and 21 (23.1%) females falling in inclusion criteria were operated by same surgeons with same implant i.e. DCP.

Aizaz Saleem Khan et al¹³ in study compared two groups of 30 patients each treated with intramedullary nail and DCP. In group A, transient radial nerve palsy was observed in 3 patients (10%) and mild wound infection in 2 (6%). There was no statistical difference in infection and palsy rates between the two groups.

Naveen P.R. et al¹⁴ operated 34 patients. Out of that 18 patients were treated with DCP and 16 with interlocking nailing for fracture shaft of humerus. In the DCP group there was no incidence of post operative radial nerve palsy and infection observed but one case of non-union was found as compared to interlocking nailing.

Mohammad Shoaib Khan et al⁵ in study operated 15 patients with bone grafting and DCP. Out of 15 patients the age range was 20-80 years, 12(80%) were male and 03(20%) female. Two patients(13.33%) got neuropraxia of radial nerve which resolved within 3 months time. 02 patients (13.33%) developed shoulder stiffness which resolved after exercise.

M.Walker et al¹⁵ observed that Outcomes of plate fixation of humeral shaft fractures are generally very good, with union rates in the 92% to 96% range, time to union averaging around 12 weeks, and complication rates ranging from 5% to 25%.

In another study Huerta Lazcarro et al¹⁶ evaluated 87 patients with male (61 %) and female (39 %). DCP plate was used in (80 %) and intramedullary nail in (20 %) patients ($p < 0.05$). He found Radial nerve lesion at the beginning and end of the study: 15 (22%) of 70 patients vs. 1 (5.5%) of 17 patients operated with DCP plate vs. intramedullary nail respectively. Of the 16 radial nerve lesions on total (100%), 12 presented with neuroapraxia (10.4%) that included a patient treated with intramedullary nailing and 4 (3.4%) axonotmesis treated with open reduction and internal fixation with DCP.

Fang-Yao Chiu et al¹⁷ operated 105 patients with DCP, which included 66 males and 39 females. Complications included 4 patients (3.81 %) with temporary radial-nerve palsies, and 3 patients (2.85%) with wound infections.

In my study 87 patients (95.60%) had no neurological deficit while 4 patients (4.40%) had neurological deficit on 1st postoperative day. On 12th postoperative day only 9 patients (9.9%) had superficial wound infection while 82 patients (90.1%) have no wound infection.

R. G. McCormack et al¹² randomized prospectively 44 patients with fractures of the shaft of the humerus to open reduction and internal fixation by either an intramedullary nail (IMN) or a dynamic compression plate (DCP). Patients were followed up for a minimum of six months. Findings suggest that open reduction and internal fixation with a DCP remains the best treatment for unstable fractures of the shaft of the humerus. Fixation by IMN may be indicated for specific situations, but is technically more demanding and has a higher rate of complications.

A. B. Putti et al¹⁸ reported that in the respective IMN and DCP groups, non-union rates have been reported to be 8% and 2 to 4%, whereas rates of iatrogenic radial nerve palsy were 2.6 to 14.3% and 2 to 5%. This study concludes that there is less complication rates with application of DCP as compared to IMN. In a randomized controlled trial, comparison of interlocking nailing with compression plating was done and concluded that the dynamic compression plating is better than interlocking nail for fracture shaft of humerus.¹⁹

A recent meta-analysis conducted on these studies revealed that patients in the plated group had a lower rate of reoperation (6% vs. 18%, $p < 0.03$), and a lower rate of shoulder pain (1% vs. 21%, $p < 0.002$).²⁰ There were also more nonunion in the nail group (8/73, 11%) than in the plate group (5/83, 6%), although this difference did not reach statistical significance with the numbers available. These studies certainly did not confirm the theoretical advantages of locked intramedullary nailing of humeral shaft fractures and have re-established compression plating as the treatment of choice for the majority of these injuries.

CONCLUSION

Humeral shaft fracture is a common fracture among the young age with high energy trauma and old age with low energy fall. The primary goal of treatment is to make the patient return to

his or her pre-fracture functional status. In my study there are least chances of radial nerve injury and wound infection as well as early return to normal life after fixing fracture shaft of humerus with DCP. Internal fixation with DCP is the best treatment modality in our setup.

REFERENCES

1. Spiguel AR, Steffner RJ. Humeral shaft fractures. *Curr Rev Musculoskelet Med.* 2012;5:177–83.
2. Andrew H, Crenshaw JR, Edward A, Perez. Fractures of the shoulder, arm and forearm. In: Canale ST, Beaty JH. *Campbell's operative orthopaedics* 11th ed. St. Louis: Mosby; 2008. p.3371-460.
3. Denard A Jr, Richards JE, Obrebsky WT, Tucker MC, Floyd M, Herzog GA. Outcomes of nonoperative vs operative treatment of humeral shaft fractures: a retrospective study of 213 patients. *Orthopedics.* 2010;33:552.
4. Idoine JD, 3rd, French BG, Opalek JM, Demott L. Plating of acute humeral diaphyseal fractures through an anterior approach in multiple trauma patients. *J Orthop Trauma.* 2012;26:9–18.
5. Khan MS, Sahibzada AH, Khan AM, Sultan S, Younas M, Khan AZ. Outcome of plating, bone grafting and shortening of non-union humeral diaphyseal fracture. *J Ayub Med Coll Abbottabad.* 2005;17(2):44-6.
6. Changulani M, Jain UK, Keswani T. Comparison of the use of the humerus intramedullary nail and dynamic compression plate for the management of diaphyseal fractures of the humerus. A randomized controlled study. *Int Orthop* 2007;39:1-5.
7. Denies E, Nijis S, Sermon A, Broos P. Operative treatment of humeral shaft fractures. Comparison of plating and intramedullary nailing. *Acta Orthop Belg.* 2010;76:735-42.
8. Singiseti K, Ambedkar M. Nailing versus plating in humerus shaft fractures: a prospective comparative study. *Int Orthop* 2010;34:571-6.
9. Jiang R, Luo CF, Zeng BF, Mei GH. Minimally invasive plating for complex humeral shaft fractures. *Arch Orthop Trauma Surg.* 2007;127:531-5.
10. Paris H, Tropiano P, Clouet D'orval B, Chaudet H, Poitout DG. Fractures of the shaft of humerus: systemic plate fixation. Anatomic and functional results in 156 cases and review of literature. *Rev Chir Orthop Reparatric Appar Mot.* 2000;86:346-59.
11. Auch J, Renner N, Rikli D. Intramedullary nailing of humeral shaft fractures-initial experiences with an undreamed humerus nail. *Swiss Surg.* 2000;6:299-303.
12. McCormack RG, Brien D, Buckley RE, McKee MD, Powell J, Schemitsch EH. Et al; Fixation of fractures of the shaft of the humerus by dynamic compression plate or intramedullary nail. A prospective, randomised trial. *J Bone Joint Surg Br* 2000;82:336-9.
13. Khan AS, Afzal W, Anwar A. Comparison of shoulder function, radial nerve palsy and infection after nailing versus plating in humeral shaft fractures. *J Coll Physicians Surg Pak.* 2010;20:253-7.
14. Naveen PR, Chaitanya PR. "Comparative study between the dynamic compression plating (DCP) and the intramedullary interlocking nailing in diaphyseal fractures of the humerus in adults". *J Evol Med Dent Sci.* 2013; 2:8704-12
15. Walker M, Palumbo B, Badman B, Brooks J, Gelderen JV, Mighell M. Humeral shaft fractures: a review. *J shoulder and elbow surg* 2011; 20:833-44.
16. Huerta Lazcarro J, Luna Pizarro D. A comparison of the prevalence of radial nerve lesion after fixation of humeral shaft fractures with dynamic compression plate versus intramedullary nailing. *Acta Orthop Mex.* 2008;22:287-91.
17. Hsu TL, Chiu FY, Chen CM, Chen TH. Treatment of nonunion of humeral shaft fracture with dynamic compression plate and cancellous bone graft. *J Chin Med Assoc.* 2005;68:73-6.
18. Putti AB, Uppin RB, Putti BB. Locked intramedullary nailing versus dynamic compression plating for humeral shaft fractures. *J Orthop Surg (Hong Kong).* 2009;17:139-41.

-
19. Chaudhary P, Karn NK, Shrestha BP, Khanal GP, Rijal R, Maharjan R, et al. Randomized controlled trial comparing dynamic compression plate versus intramedullary interlocking nail for management of humeral shaft fracture. *Health Renaissance*. 2011; 9:61-6.
20. Bhandari M, Devereaux PJ, McKee MD, Schemitsch EH. Compression plating versus intramedullary nailing of humeral shaft fractures: a meta-analysis. *Acta Orthop*. 2006;77:279-84.

AUTHORS

- **Dr. Muhammad Nadeem Yousaf**
Medical Officer, Orthopedics
Allied Hospital, Faisalabad
- **Dr. Shahabud Din**
Post Graduate Resident, Orthopedics
Allied Hospital, Faisalabad
- **Dr. Muhammad Rizwan Akram**
Post Graduate Resident, Orthopedics
Allied Hospital, Faisalabad
- **Prof. Dr. Ajmal Yasin**
Head of Orthopedics
Punjab Medical College, Faisalabad
- **Dr. Rana Dawood Ahmad Khan**
Assistant Professor, Orthopedics
Punjab Medical College, Faisalabad

Submitted for Publication: 23-05-2014

Accepted for Publication: 26-08-2014
After minor revisions