

Frequency of metastasis detection with diffusion-weighted whole-body imaging with background body signal suppression

Amna Rehan, Rehan Riaz, Zonaira Shabir, Salma Zafar, Anjum Mehdi

ABSTRACT

Objective: To determine the frequency of metastasis detection with diffusion-weighted whole-body imaging with background body signal suppression. **Study Design: A Cross sectional study. Place and Duration of Study:** The study was conducted at Punjab Medical College and Allied hospital Radiology and Oncology departments, Faisalabad from January 14, 2010 to May 28, 2012. **Patients and Methods:** A total number of 86 patients of all ages and both sexes with histopathological diagnosis of carcinoma presenting to the outdoor department and admitted in oncology department of Punjab Medical college and Affiliated hospital were selected. Whole-body MRI was performed using a 1.5-Tesla system (Intera Release 9; Philips, Best, The Netherlands) with a Mobi-Trak moving tabletop and b value of 1000. Both the T1 weighted and the STIR images at each station were reconstructed.

On MRI, a lesion of high signal intensity on DWIBS, a lesion of high signal intensity on STIR images and low signal intensity on T1 weighted images was considered to be a suspected metastasis. **Results:** Out of 86 patients, 70 (81.4%) had metastasis. Osseous metastasis was detected in 13 (18.6%) patients however in 57 (81.4%) patients, both osseous and extra osseous metastasis were detected. Liver metastasis was detected in 47 (82.5%) patients out of 57 patients with extra osseous metastasis. Adrenal metastasis was found in 12 (21.1%) patients, brain in 13 (22.8%) patients, lung in 19 (33.3%) patients, renal in 6(10.5%) patients and peritoneal dissemination was seen in 5 (8.8%) patients. Nodal metastasis was detected in 57 patients and maximum number of 19 lymph nodes were detected. **Conclusion:** DWIBS MRI is helpful in the early diagnosis of metastasis. **Key Words:** DWIBS, metastasis.

INTRODUCTION

Cancer is the second leading cause of death in developed countries, is among the three leading causes of death for adults in developing countries, and is responsible for 12.5% of all deaths worldwide.¹

Once a malignant tumor is detected, determination of disease extent (staging) is important for appropriate treatment planning and determining prognosis. Imaging plays a pivotal role in cancer staging.

Magnetic resonance imaging (MRI) is a noninvasive method of mapping the internal structure and certain aspects of function within the body. It uses non ionizing electromagnetic radiation and appears to be without exposure-related hazard. It employs radiofrequency radiation in the presence of carefully controlled magnetic fields in order to produce high quality cross-sectional images of the body in any plane.² Whole-body MRI has become feasible with recent developments in MRI, including fast image acquisition, hardware innovation such as tabletop extenders, and the implementation of dedicated software.^{3,4}

Diffusion-weighted magnetic resonance imaging (DWI) provides functional information and can be used for the detection and characterization of

Corresponding Author:

Dr. Amna Rehan
Senior Registrar Radiology,
Allied Hospital Faisalabad
Tel. +92 321-7536782
E-mail: amna.rehan11@hotmail.com

pathologic processes, including malignant tumors; it may therefore be of value in staging and follow-up imaging of malignant tumors.¹

In 2004, Takahara et al. reported a unique concept of whole-body DWI, called “diffusion-weighted whole-body imaging with background body signal suppression” (DWIBS). This technique intentionally uses free breathing scanning rather than breath holding or respiratory triggering to visualize (moving) visceral organs and their lesions. This also visualizes metastatic lesions in static tissue i.e. visceral organs, such as the spleen and kidneys. This concept offers a wide range of potential applications in whole-body oncological imaging.¹

In a recent study, the diagnostic value of whole body magnetic resonance (MR) imaging (WB-MRI) using diffusion-weighted images (DWI) for detecting bone metastasis was compared with that of skeletal scintigraphy (SS). In 33.3% patients, a total of 52 metastatic bone lesions were identified. For these 52 lesions, the mean sensitivity was 96% and the positive predictive value (PPV) was 98% and authors concluded that WB-MRI that included DWI was useful for detecting bone metastasis.⁵

The rationale of this study is that since the DWIBS MRI facility is available at all the tertiary care hospitals, it will help in the early diagnosis of metastasis which will benefit both the patient and the oncologist in the treatment.

MATERIALS & METHODS

This cross sectional study was conducted from January 14, 2010 to May 28, 2012 included the patients of all ages including both sexes with histopathological diagnosis of carcinoma. Patients with contraindication to conventional MR imaging (e.g. metal implants, pace maker, etc.) were excluded.

A total number of 86 patients of all ages and both sexes with histopathological diagnosis of carcinoma presenting to the outdoor department and admitted in oncology department of Punjab Medical college and Affiliated hospital were selected.

Whole-body MRI was performed using a 1.5-Tesla system (Intera Release 9; Philips, Best, The Netherlands) with a Mobi-Trak moving tabletop

and b value of 1000. Whole-body coverage was obtained using large field of view coronal images in five or six table positions. The field of view was 53 cm with a 3 cm overlap between each station. All images were acquired with a Q-body phased-array coil, and a slice thickness will be 6 mm. T1 weighted imaging was obtained with the following parameters: fast spin-echo sequence repetition time (TR) 537 milliseconds (m sec), effective echo time (TE) 18 milliseconds, echo train length 4, one signal acquired and matrix 512, slice orientation was coronal. Short tau inversion recovery (STIR) images were obtained with the following parameters: TR 2397 m sec, effective TE 64 m sec, TI of 165, echo train length of 24, one signal acquired and matrix 512, slice orientation was coronal. DWIBS images slice orientation will be axial and matrix 352. Both the T1 weighted and the STIR images at each station were reconstructed.

The MR images were performed in radiology department of Allied hospital and read by a consultant radiologist. The reader scored the number and sites of metastasis depicted at each examination.

On MRI, a lesion of high signal intensity on DWIBS, a lesion of high signal intensity on STIR images and low signal intensity on T1 weighted images was considered to be a suspected metastasis.

Statistical Analysis

Data was analyzed using SPSS version 10. Quantitative variable i.e. age, size and number of metastasis are presented as mean and standard deviation. Qualitative variable i.e. gender, presence and site of metastases are presented as frequency and percentage. All the data is presented in the form of tables and graphs.

RESULTS

In this cross sectional study age of patients was between 32-80 years with standard deviation of 12.03 and mean age of 56.87 yrs.

Regarding distribution of gender of the cases, out of 86 patients 37 (43%) were males and 49 (57%) were females.

Regarding frequency of detection of metastasis, out of 86 patients, 70 had metastasis. In 16

patients no metastasis were detected. In terms of frequency 81.4% patients had metastasis where as 18.6% had no metastasis.

Out of 86 cases, 70 were true positive (81.4%) that is these patients showed metastasis both on skeletal scintigraphy and DWIBS MRI. 16 (18.6%) patients were true negative as they showed no metastasis on skeletal scintigraphy and on DWIBS MRI as well.

On DWIBS MRI osseous metastasis were detected in 13 (18.6%) patients however in 57 (81.4%) patients, both osseous and extra osseous metastasis were detected out of 70 patients(table 1).

Liver metastasis was detected in 47 (82.5%) patients out of 57 patients with extra osseous metastasis. Only 10 (17.5%) had no liver metastasis(table 2).

Adrenal metastasis was found in 12 (21.1%) patients, brain in 13 (22.8%) patients, lung in 19 (33.3%) patients, renal in 6(10.5%) patients and peritoneal dissemination was seen in 5 (8.8%) patients (table 3).

Nodal metastasis was detected in 57 patients and maximum number of 19 lymph nodes were detected with standard deviation of 4.86 (table 4). Size of the lesion was also detected by DWIBS MRI which ranged from 2.20 mm to 280.00 mm with a standard deviation of 41.44 and mean size of 57.37 mm.

Number of the metastasis ranged from 3 to maximum total of 34 metastasis in a patient with a standard deviation of 7.63 and mean number of 17.92 metastases.

Table 1: Site of metastasis

	Frequency	Percent
Osseous	13	18.6
Extra osseous	20	28.6
Both osseous and extra osseous	37	52.9
Total	70	100.0

Fig 1: Site of metastasis

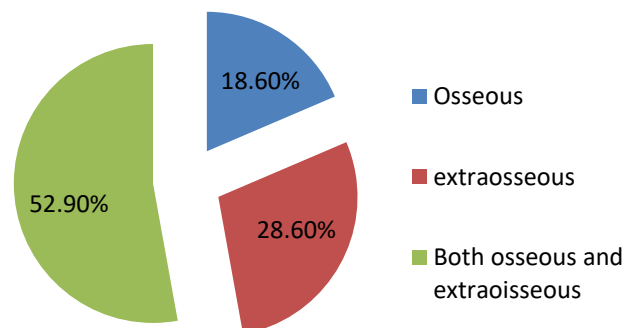


Table 2: Liver metastasis

	Frequency	Percent
Yes	47	82.5
No	10	17.5
Total	57	100.0

Table 3: Other sites of metastasis

	Frequency	Percent
Adrenal	12	21.1
Brain	13	22.8
Kidney	06	10.5
Lungs	19	33.3
Peritoneal dissemination	05	8.8
Spleen	02	3.5
Total	57	100.0

Table 4: Nodal metastasis

N	57
Minimum number of nodes	0
Maximum number of nodes	19
Mean	10.04
Standard deviation	4.86

DISCUSSION

Diffusion-weighted magnetic resonance imaging (DWI) provides functional information and can be used for the detection and characterization of pathologic processes, including malignant tumors; it may therefore be of value in staging and follow-up imaging of malignant tumors.(10) Like bone scanning, whole body MRI offers a whole-body overview of disease and hence is particularly useful in assessing diseases such as carcinoma and lymphoma that infiltrate throughout the body both in bones and in soft tissues. WB-MRI with DWIBS is to be considered as alternative tool to conventional whole-body methods for tumor staging and during follow-up in cancer patients (6) In the present study DWIBS MRI detected both osseous and extraosseous metastasis in a patient with known malignancy in the same setting. Another important benefit is that there is no radiation burden for the patient in DWIBS MRI. As the bony metastasis are also detected and there is no need for skeletal scintigraphy for detection of bony metastasis. At present, oncoimaging for skeletal metastasis relies entirely on bone scan or PET scan for whole body imaging; although there are concerns about radiation hazards, economic constraints, scarce availability and prolonged waiting periods. DWIBS MRI can be an effective alternative especially where bone scan or PET scan is not available.(7)

The study is supported by the previous study by Ballon et al. which also reported whole-body DWI during free breathing. The study aimed to visualize metastatic lesions in static tissue (bone marrow); however, they additionally found that visceral organs, such as the lungs, adrenals, spleen

and kidneys, were also visualized. DWIBS highlights areas with restricted diffusion, such as occurs in many malignant primary and metastatic tumours, and provides an outstanding visualization by suppressing the background signals.(8)

DWIBS MRI provides one stop shopping that is it detects maximum number of visceral metastatic deposit without any additional discomfort to patient in moving from one diagnostic suit to another. In addition, this will be time and energy saving for the patient and provides no additional burden to environment. However, it is also possible to perform a time-efficient whole-body examination using only one surface coil with limited coverage. Furthermore, spacers were placed between both tables to create space to move the lower part of the surface coil from one station to the next. As a result, the patient can remain in the same position, repositioning of the surface coil to image the next station required only little additional time (<1 min per station), and 3D alignment among the imaged stations was maintained. After completion of the examination, separately imaged stations were merged with sophisticated software, creating the whole-body image.

The DWIBS sequence has been developed with the aim to detect lymph nodes and to differentiate normal and hyperplastic from metastatic lymph nodes. This may be possible caused by alterations in microcirculation and water diffusivity within cancer metastases in lymph nodes. DWIBS is a new diffusion weighted imaging technique for the whole body that produces PET-like images. Inverting the gray scale of DWIBS images makes them resemble PET-like images. DWIBS images are comparable with PET images and provide applications from the visualization lymph nodes and detection of lesions throughout the body.(9)

WB-MRI with DWIBS is to be considered as alternative tool to conventional whole-body methods for tumor staging and during follow-up in cancer patients.(6)

CONCLUSION

Although the exact value of DWIBS still has to be established, it has potential use in tumor staging, monitoring response to cancer therapy, and in the

detection of tumor persistence or recurrence. DWIBS sequences add functional information to whole body mri protocol with conventional morphological sequences with a relatively fast acquisition and lack of ionizing radiation-improve the sensitivity and specificity of WB MR imaging whole body mri with conventional and DWIBS sequences could be considered as a promising alternative, noninvasive method for detection and staging of neoplastic diseases, especially among young patients.

REFERENCES

1. Kwee TC, Takahara T, Ochiai R, Nievelstein RA, Luijten PR. Diffusion-weighted whole-body imaging with background body signal suppression (DWIBS): features and potential applications in oncology. *EurRadiol* 2008;18:1937–52.
2. Wilkinson ID, Paley MNJ. Magnetic resonance imaging: basic principles. In: Adam A, Dixon A, editors. *Grainger & Allison's diagnostic radiology: a textbook of medical imaging*. 5th ed. London: Churchill Livingstone;2008:56-67.
3. Johnston C, Brennan S, Ford S, Eustace S. Whole body MR imaging: applications in oncology. *Eur J SurgOncol* 2006;32:239–46.
4. Yousuf N. Functional Magnetic resonance imaging. *Pak J NeurolSci* 2006; 1:106-9.
5. Nakanishi K, Kobayashi M, Nakaguchi K, Kyakuno M, Hashimoto N, Onishi H, et al. Whole-body MRI for detecting metastatic bone tumor: diagnostic value of diffusion-weighted images. *MaganReson Med Sci* 2007;6:147-55.
6. Manenti G, Cicciò C, Squillaci E, Strigari L, Calabria F, Danieli R, Schillaci O, Simonetti G. Role of combined DWIBS/3D-CE-T1w whole-body MRI in tumor staging: Comparison with PET-CT. *EurRadiol*.2012; 81(8):1917–25.
7. Gandage SG, Kachewar SG, Aironi VD, AD Nagapurkar. A comparative study of whole body DWIBS MRI versus bone scan for evaluating skeletal metastases. *Australas Med J*. 2012; 5(12): 619–22.
8. Ballon D, Watts R, Dyke JP, Lis E, Mooris MJ, Scher HI, et al. Imaging therapeutic response

in humanbone marrow using rapid whole-body MRI. *MagnReson Med*.2004;52:1234–8.

9. Kachewar SG. Using DWIBS MRI technique as an alternative to bone scan or PET scan for whole-body imaging in oncology patients. *ActaRadiol*. 2011;52:788.
10. Vassiliou V, Andreopoulos D, Frangos S, Tselis N, Giannopoulou E, Lutz S. Bone metastases: assessment of therapeutic response through radiological and nuclear medicine imaging modalities. *R CollRadiol*. 2011;23(9):632-45.

AUTHORS

- **Dr. Amna Rehan**
Senior Registrar of Radiology
Allied Hospital Faisalabad
- **Dr. Rehan Riaz**
Senior Registrar of Cardiology,
Faisalabad Institute of Cardiology
Faisalabad
- **Dr. Zonaira Shabir**
Post Graduate Trainee of Radiology
Allied Hospital, Faisalabad
- **Dr. Salma Zafar**
Post Graduate Trainee of Radiology
Allied Hospital, Faisalabad
- **Dr. Anjum Mehdi**
Associate Professor of Radiology
PMC / Allied Hospital, Faisalabad

Submitted for Publication: 26-09-2014

Accepted for Publication: 15-11-2014