

Frequency of Carotid Artery Stenosis in Ischemic Stroke

Umair Ahmed, Aamir Shaukat, Asim Shaukat, Hooria Aamir, Awais Ahmed

ABSTRACT

Stroke continues to be a significant cause of morbidity and mortality throughout the world. According to the world health organization, 15 million people suffer stroke worldwide annually. Despite maximal medical management, carotid artery atherosclerosis leading to stenosis continues to portend a poor prognosis. Conservative management frequently fails in this disease, leaving patients at high risk for cerebral infarction and death.

Objective: To determine the frequency of carotid artery stenosis in patients with stroke using Doppler Ultrasonography. **Study design:** cross-sectional analytical study. **Setting:** outpatient and emergency department of Medical Unit-I, Allied Hospital, Faisalabad.

Duration of study: Study was carried out over a period of seven months from 01-03 2014 to 30-09-2014. **Subjects and methods:** A total of 100 cases were included in this study. Every patient was undergone a list of investigation

including lipid profile, electrocardiography (ECG), X-ray chest (PA), computed tomography (CT) scan brain and echocardiography to rule out any cardiac source of embolism. **Results:** Out of 100 cases, 12 patients (12%) were between 18-40 years old, 34 patients (34%) were 41-60 years of age while 54 patients (54%) were 61-80 years old. Mean age of the patients was 51.9 ± 5.1 . Regarding gender distribution, 62 patients (62%) were male and 38 patients (38%) were female. Of 100 patients, 56 patients (56%) had carotid stenosis on color Doppler Ultrasonography of carotid arteries. 29 patients (51.8%) had mild stenosis, 17 patients (30.3%) had moderate stenosis and 10 patients (17.9%) severe stenosis. **Conclusion:** It is concluded that carotid artery stenosis is strongly associated with ischemic stroke. Doppler studies are recommended for the high risk patients for the primary as well as secondary prevention of ischemic stroke. **Key Words:** Carotid artery stenosis, Infarctive stroke, Frequency

INTRODUCTION

Stroke is the third most common cause of death and chronic disability in elderly patients worldwide.¹ Stroke remains one of the most devastating of all neurological diseases, often causing death or gross physical impairment or disability.² Atherosclerosis of the carotid artery is an important mechanism underlying cerebrovascular disease, and it has been associated with stroke.³

In Pakistan, annual estimated stroke incidence is close to 250 per 100,000 population,

which means that there are 350,000 new stroke patients every year in the country.⁴ Atherosclerosis occurring mostly at the bifurcation and proximal segments of the internal carotid artery, is the leading cause of ischemic stroke, accounting for up to 40% of such events in Western countries.⁵ In another study, significant atherosclerosis was present in 21% of the patients.⁶ Duplex ultrasound is inexpensive, non-invasive and can provide functional and anatomical information about vessel stenosis and plaque morphology. On the basis of rendered evidence indicating benefit of carotid endarterectomy/stenting in patients with >70% symptomatic carotid stenosis current stroke guidelines recommended use of carotid Doppler ultrasonography in all patients with recent stroke or Transient Ischemic attack (TIA).⁷ Duplex ultrasonography is currently the principal and

Corresponding Author:

Dr. Umair Ahmed
Assistant Professor of Medicine,
PMC / DHQ Hospital, Faisalabad
Tel. +92 300-9669550
E-mail: dr.umairahmed123@gmail.com

undoubtedly the most accurate non-invasive diagnostic modality available for evaluation of carotid artery stenosis. It provides information about the degree of carotid stenosis, the velocity and character of blood flow and plaque morphology. It is a low cost low risk and portable alternative to catheter-based angiography.³ The data regarding frequency of carotid artery disease in Pakistan are limited. One hospital-based study showed a frequency of 12% "high-grade" carotid stenosis in patients with ischemic stroke.⁵ Another study showed that when carotid Doppler ultrasonography was done on patients with cerebral infarction, showed that 48.5% patients had some evidence of carotid atherosclerosis.⁶ The frequency of significant carotid artery atherosclerosis which was defined as more than 60% stenosis of lumen carotid artery in patients with ischemic stroke was 21%. The rationale of this study was to detect an established and preventable cause of stroke with the help of Doppler Ultrasonography, which may subsequently help to plan out future treatment modality (medical and/or surgical) for prevention of further cerebrovascular events using color Doppler imaging, which is a non-invasive, cheap and readily available investigation modality.

Objective: The objective of the study was:

To determine the frequency of carotid artery stenosis in patients with infarctive stroke.

MATERIALS AND METHODS

It was a Cross-sectional analytical study conducted in Medical Unit 1 Allied Hospital Faisalabad. 100 patients both male and female presenting in Outpatient and Emergency Department with clinical and radiological confirmed diagnosis of infarctive stroke between 01-03 2014 to 30-09-2014 were included. Non-probability consecutive sampling technique was used.

Patients with cerebral contusions, intra-cerebral, subarachnoid, subdural hemorrhage and patients presenting with stroke secondarily to cardiac causes were excluded from the study. After taking permission from hospital ethical committee. All patients aged 18 years or older presenting in outpatient, emergency departments with clinical, radiological diagnosis of infarctive stroke were

included in the study by taken detailed history and examination. Every patient underwent a list of investigations including lipid profile, electrocardiography (ECG), X-RAY chest (PA), compared tomography (CT) scan brain and echocardiography to rule out any cardiac source of embolization. Patients with cerebral contusions, intra-cerebral, subarachnoid, subdural, and extradural hemorrhage was excluded by performing CT scan brain.

Doppler ultrasound study of carotid arteries were performed and reported by Consultant Radiologist. Examination was started with the longitudinal survey of cervical carotid arteries with the transducer in a lateral position. The extent of plaque, its morphological characteristics, and especially degree of luminal narrowing was noted. The carotid arteries were re-examined from an anterior transducer position. The diameter of the residual lumen and the external diameter of the artery at the same level was measured and the IMT (intima media thickness) of the carotid arteries were calculated. Doppler study was performed using Toshiba Nemio 20 with a linear transducer of 7.5MHz, with subject lying in the supine position and the head slightly tilted to opposite side. Initially, the common and internal carotid arteries were scanned transversally and longitudinally, whereby distribution of atheromatous plaques was roughly evaluated. During the initial scanning, optimal insonation angles were determined for the estimation of respective plaque heights, and the measurements were performed on the frozen frame, perpendicular to the vascular walls. Bilateral carotid arteries were examined by the same procedure. Carotid stenosis /occlusion was diagnosed by the commonly used criteria. The diameter of the residual lumen and the external diameter of the artery at the same level were measured and the degree of stenosis was calculated using the following relationship:

$$\text{Percent stenosis} = \frac{D-d}{D} \times 100$$

where D is vessel wall-to-wall diameter and d is patent vessel diameter. According to Consensus Conference of Society of Radiologists in Ultrasound 2002, mild stenosis was defined as less than 50% stenosis, moderate stenosis

between 50-70% and severe more than 70% stenosis.

Data were entered and analyzed on SPSS version 10.0. Descriptive statistics were used for all variables. Mean and standard deviation was calculated for quantitative variables like age. Frequency was calculated for all qualitative variables like gender and carotid artery stenosis. All the data were presented in the form of tables, graphs.

RESULTS

A total of 100 patients of infarctive stroke were included in this study during the study period of six months from 01-03 2014 to 30-09-2014.

Out of 100 cases, 12 patients (12%) were between 18-40 years old, 34 patients (34%) were 41-60 years of age while 54 patients (54%) were 61-80 years old. Mean age of the patients was 61.9±5.8 (Table-1).

Regarding gender distribution, 62 patients (62%) were male and 38 patients (38%) were female (Table-2).

Of 100 patients with ischemic infarction on CT brain, 56 patients (56%) had carotid stenosis on color doppler ultrasonography of carotid arteries. 29 patients (51.8%) had mild stenosis, 17 patients (30.3%) had moderate stenosis and 10 patients (17.9%) severe stenosis as per according to Consensus Conference of Society of Radiologists in Ultrasound 2002 criteria.

Table-1: Distribution of Cases by Age

Age (Year)	Number	Percentage
18-40	12	12.0
41-60	34	34.0
61-80	54	54.0
Total	100	100.0
Mean ± SD	51.9±5.1	

Table-2: Distribution of Cases by Gender

Sex	Number	Percentage
Male	62	62.0
Female	38	38.0
Total	130	100.0

Table-3: Frequency of carotid artery stenosis n=58

Degree of Stenosis	Percent diameter of stenosis	Number of patients	Percentage
Mild	<50 %	29	51.8%
Moderate	50-70 %	17	30.3%
Severe	> 70 %	10	17.9%

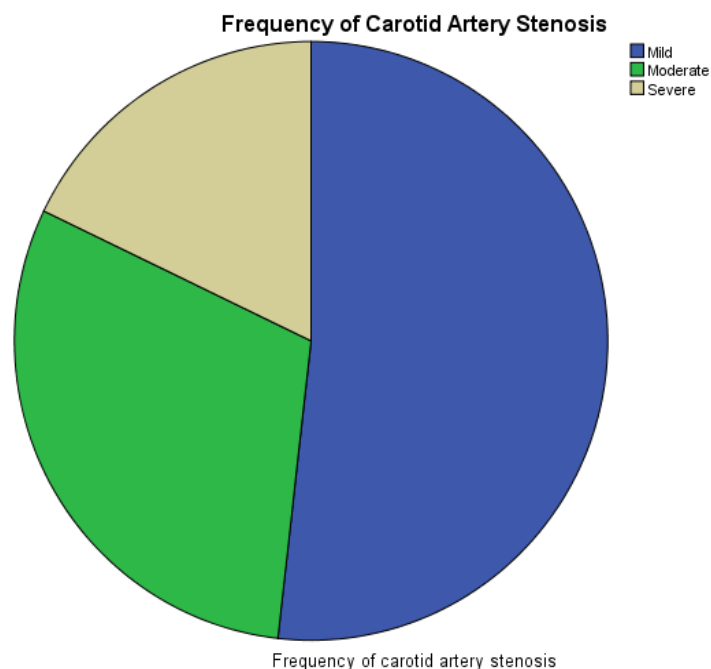


Figure 1: Frequency of Carotid Artery Stenosis

DISCUSSION

Stroke is the most common life-threatening neurological disorder and the most important single cause of disability. Among all deaths, 40-

50% are due to vascular events of which 10% are due to stroke.⁸ Carotid artery stenosis (CAS) is a major risk factor for stroke and for the symptomatic cerebrovascular disease. Carotid artery stenosis is strongly associated with ischemic stroke.⁹ In a study Carotid artery stenosis was seen in 39% of the patients with infarctive stroke.⁹ Large multicenter prospective studies such as North American Symptomatic Carotid Endarterectomy Trial (NASCET) and European Symptomatic Trial (EST) have shown the etiological significance of carotid lesions in ischaemic stroke patients.¹⁰ The risk of ischaemic stroke increases with the degree of carotid stenosis and increased carotid artery stiffness measured by carotid ultrasound are associated with stroke.¹¹ Because patients with symptomatic occlusion of the internal carotid artery (ICA) and compromised cerebral blood flow are at risk for future ischaemic infarcts therefore early identification and accurate determination of the degree of carotid artery stenosis using carotid Doppler ultrasonography is useful in risk-factor management, with appropriate medical or surgical intervention.³

In our study out of 100 patients with ischemic infarction on CT brain, 56 patients (56%) had carotid stenosis on color doppler ultrasonography of carotid arteries. In a study by Mozzam Ali et al¹² carotid stenosis was found in 48.5% of patients. In another study by Laeeq Ahmed et al¹³ carotid stenosis was found in 44% of the patients.

Older age is an important and well known risk factor for the development of Carotid artery atherosclerosis and infarctive stroke. In our study the majority of patients having stroke (54%) were 60 years old or more. These findings were consistent with certain international studies. An Indian study by Sethi et al¹⁴ found that mean age of patients with carotid lesion was 60.03 years

In our study 10 patients had (17.9%) severe stenosis i.e more than 70%. In a study by Alexandrore et al¹⁵ who reported stenosis of equal or greater than 70% in 17% of 348 patients. In a Pakistani study by Khan et al¹⁶ severe stenosis was found in 18.8% of the patients.

CONCLUSION

It is concluded that carotid artery stenosis is strongly associated with ischaemic stroke. High

risk patients should be screened by Doppler ultrasonography for the presence of carotid stenosis in order to plan out medical / surgical intervention for the primary as well as secondary prevention of cerebrovascular events.

REFERENCES

1. Clarke CRA. Neurological disease. In: Kumar P, Clark M, editors. Clinical Medicine. 7th ed. Philadelphia: Saunders; 2009. p. 1095.
2. Mukherjee D, Patil CG. Epidemiology and the Global Burden of Stroke—Situation in Turkey. *World Neurosurgery* 2014;81: e35-36.
3. Byrnes KR, Ross CR. The Current role of Carotid duplex Ultrasonography in the management of Carotid Atherosclerosis: Foundations and Advances. *Int J Vasc Med* 2012;2012: 1878872. Epub Mar 7.
4. Khatri IA, Wasay M. Can we stop the stroke epidemic in Pakistan? *JCPSP* 2011; 21:195-96.
5. Wasay M, Azeemuddin M, Masroor I, Ahmed R, Khealani BA. Frequency and outcome of carotid. Atheromatous Disease in patient with stroke in Pakistan. *Stroke* 2009;40:708-12.
6. Atif MA, Ali H, Mahmood T. Frequency of carotid atherosclerosis in cerebral infarction. *Pak J Med Sci* 2008;24:69-73.
7. Rom M, Mukharjee D, Clair DG. Carotid artery stenting vs endoarterectomy. *Eur Heart J* 2009;30:704.
8. Nagaraj SK, Pai P, Bhat G, Hemalatha A. Lipoprotein (a) and other lipid profile in patients with thrombotic stroke: Is it a reliable marker? *Journal of laboratory physicians.* 2011;3:28-32.
9. Sheikh NA, Bhatti S, Irfan M, Khatri G, Vaswani AS, Jakhrani N. Frequency, characteristics and risk factors of Carotid Artery Stenosis in ischaemic stroke patients at Civil Hospital Karachi. *J Pak Med Assoc* 2010;60: 8-12.
10. Tan TY, Chang KC, Liou CW, Reynolds PS, Tegeler CH. Lack of relationship between severity of stroke and severity of extracranial lesion in Taiwanese first-ever ischaemic stroke patients. *J Neuroimaging* 2001; 11: 381-4.
11. Yang EY, Chambless L, Sharrett R, Virani SS, Liu X, Tang Z et al. Carotid Arterial Wall Characteristics Are Associated With Incident

-
- Ischemic Stroke But Not Coronary Heart Disease in the Atherosclerosis Risk in Communities (ARIC) Study. Stroke.2012; 43: 103-108
12. Atif MA, Ali H, Mahmood T. Frequency of carotid atherosclerosis in cerebral infarction. Pak J Med Sci 2008; 24: 69-73.
 13. Ahmad L. Hyperlipidaemia and its correlation with carotid artery occlusion in patients with ischemic stroke (Dissertation) Karachi. College of Physicians and Surgeons Pakistan 2002.
 14. Sethi SK, Solanki RS, Gupta H. Color and duplex doppler imaging evaluation of extracranial carotid artery in patients presenting with transient ischaemic attack and stroke : a clinical and radiological correlation. Indian J Radiol Imaging 2005; 5: 91-18).
 15. Alexandrova NA, Gibson C, Maggisano P. Carotid artery disease and peripheral vascular disease. Stroke 1995; 26: 175.
 16. Khan SN, Vohra EA. Risk factors for stroke: A hospital based study. Pak J Med Sci 2007; 23: 17-22.

AUTHORS

- **Dr. Umair Ahmed**
Assistant Professor of Medicine
PMC / DHQ Hospital, Faisalabad
- **Prof. Dr. Aamir Shaukat**
Professor of Medicine
PMC / Allied Hospital, Faisalabad
- **Dr. Asim Shaukat**
Associate Professor of Radiology
PMC / Allied Hospital, Faisalabad
- **Dr. Hooria Amir**
Assistant Professor of Physiology
PMC / Allied Hospital, Faisalabad
- **Dr. Awais Ahmad**
Registrar of Radiology
Shifa International Hospital
Islamabad

Submitted for Publication:	02-10-2014
Accepted for Publication:	13-12-2014