

# Comparison of Efficacy of FAST and CT Scan in Patients with Blunt Abdominal Trauma

Ata UI Lateef, Asrar Ahmad Khan, Maham Mansoor Rana

## ABSTRACT

**Background:** Trauma is a major source of morbidity and mortality in modern era. Imaging and screening of trauma patients is vital in identifying the life-threatening injuries at the earliest, so appropriate therapeutic measurements can be taken immediately. The use of FAST and CT scan has replaced conventional methods in identification of intra-abdominal injuries. **Objective:** The objective of this study was to compare effectiveness of FAST and CT scan in blunt abdominal trauma patients. **Study Design:** Prospective study. **Settings:** Allied Hospital Faisalabad. **Duration:** 2 years from in 2016 to Dec 2017. **Methodology:** Patients who had come to our hospital with blunt abdominal trauma and who were stable enough to undergo both USG and CT scans were included into the study. Apart from routine tests, both USG and CT scans were performed for all the patients. **Results:** Road traffic accidents are the most common cause of trauma (58.9%), followed by fall from heights (32.1%). Liver (73.2%), spleen (51.8%), kidneys (46.4%) and pancreas (12.5%) were found to be most commonly injured intra-abdominal organs. CT scan was able to detect presence of hemoperitoneum in 100% of the patients while FAST was only able to detect it in 83.9% of patients. **Conclusions:** CT scan is a superior imaging tool for the detection of Blunt abdominal trauma compared to FAST. However, the patient needs to be hemodynamically stable for CT to be performed.

**Keywords:** Blunt abdominal trauma, CT Scans, Hemoperitoneum, FAST (focused assessment with sonography in trauma).

### Corresponding Author

Submitted for Publication: 11-10-2018

Accepted for Publication: 06-02-2019

DR. ATA UL LATEEF, Associate Professor Surgery, Faisalabad Medical University, Allied Hospital, Faisalabad-Pakistan

Contact / Email: +92 321-9661589, ataulateef@yahoo.com

**Citation:** Lateef A, Khan AA, Rana MM. Comparison of Efficacy of FAST and CT Scan in Patients with Blunt Abdominal Trauma. APMC 2019;13(1):10-3.

## INTRODUCTION

Trauma has become a significant source of morbidity and mortality due to increasing incidence of road traffic accidents. Prognosis depends on early transfer to certified trauma center and detection of life/limb threatening injuries<sup>1</sup>

Blunt abdominal trauma (BAT), most commonly resulting from motor vehicle accidents (MVA) and falls, is a mechanism of injury frequently encountered by both emergency physicians and trauma surgeon. Unlike penetrating abdominal injuries, unclear signs of traumatic injuries after BAT often leave many treatment decisions to the acumen of the clinician. The estimated prevalence of IAI in patients with BAT presenting to the emergency department (ED) were reported at 13%; those with clinically significant injuries were reported at 4.7%.<sup>2</sup>

Serial physical examinations, FAST, Computed tomography (CT) scan and diagnostic peritoneal lavage are helpful in early detection of intra-abdominal injuries.<sup>3</sup>

Patient's history and physical examination often has low sensitivity and specificity for detection of traumatic intra-abdominal pathologies. DPL is rarely of any use in pregnant or poly trauma patients and serial examinations cannot be carried out.<sup>4</sup>

Rapid diagnosis and treatment are vital to improve patient prognosis. Focused assessment with sonography in trauma (FAST) was developed in 1997 and is used worldwide as a component of Advance Trauma and Life Support. It detects free fluid in peritoneum, which may represent blood or gastric contents. Extended FAST (eFAST) has been introduced to scan

the lower chest area, revealing pneumothorax, the efficacy of a FAST scan is operator dependent and is found to be related and influenced by injury severity, patient built (obesity) and condition (hemodynamic stability), machine characteristics and resolution. Unfortunately, FAST scan has limitations, which can lead to misinterpretation or misdiagnosis. Additionally, the detection of blunt mesenteric, bowel, diaphragmatic, or retroperitoneal injuries can be difficult and often missed by FAST. Computed tomography has become the gold standard for the investigation of blunt abdominal injuries. With the development of multi-detector CT scanners, imaging time has been significantly reduced, improving its diagnostic capabilities with high sensitivity and specificity of more than 95% in detection of intraabdominal injuries and a high negative predictive value of nearly 100%.<sup>5</sup>

This study was conducted to compare early detection of injuries with CT scans and FAST in the patients with blunt abdominal trauma.

## METHODOLOGY

**Study Design:** Prospective study

**Settings:** Allied Hospital Faisalabad.

**Duration:** 2 years from in 2016 to Dec 2017.

**Methods:** This prospective study was conducted at Allied Hospital Faisalabad over a period of 2 years from in 2016 to Dec 2017. Patients irrespective of age, sex and mode of injury who had come to our hospital with blunt abdominal trauma and who were stable enough to undergo both USG and CT scans were

included into the study. If any one of the scans had come positive, Informed consent was taken for all the patients. Most of the time, USG was done first followed by CT scan with a time gap so as to include in the study. All the patients for whom both the scans had come negative and those who could not withstand both the tests specially hemodynamically unstable patients and patients with polytrauma or who were discharged within a short period after being under observation were excluded from current study.

Detailed demographic data was collected from all the patients either directly or from the relatives. After a thorough physical and clinical examination, blood was sent to the central laboratory for routine examinations such as random blood sugar, complete blood picture, hemoglobin levels, blood grouping, total blood urea and creatinine levels. Urine was sent for routine and microscopic evaluation. Chest and abdominal X-rays were also taken for all the patients.

Ultrasound and CT scans were done for all the patients to compare the outcomes, even if the USG readings were abnormal. FAST (Focused Assessment with Sonography in Trauma) was performed giving attention for the detection of free fluid in the abdomen and pelvis apart from the assessment of the individual organs. In the gall bladder and the urinary bladder, distension and the intraluminal echoes were looked for. The stomach was decompressed with a nasogastric tube to prevent the air fluid artifact. Any other leads which may interfere with the scan are removed. Contrasts were given orally and intravenously to the patients. CT sections were performed at 30 seconds for arterial and for 60-90 seconds for venous phases. In case of suspected renal trauma, delayed scanning was done. The patients with features of hemoperitoneum or intra-abdominal visceral injury were regarded as positive. When they had neither, it was considered as negative.

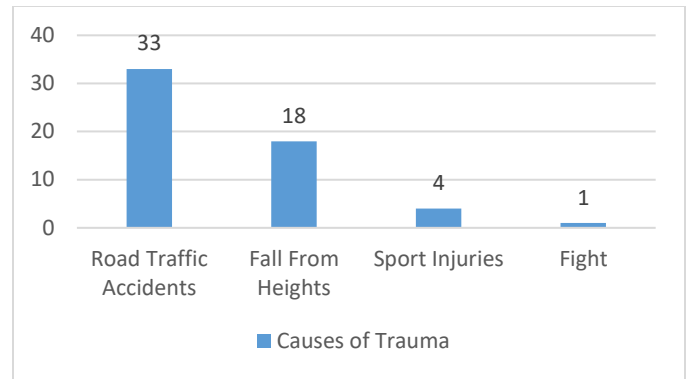
## RESULTS

Out of the 56 patients, 44 were males and 12 were females with the male to female ratio being 3.67:1. The Most common age group affected was 18-40 years. This was probably due to the fact that it is this age group that usually is involved in speeding leading to accidents (Table 1).

**Table 1: Distribution of patients in accordance with age**

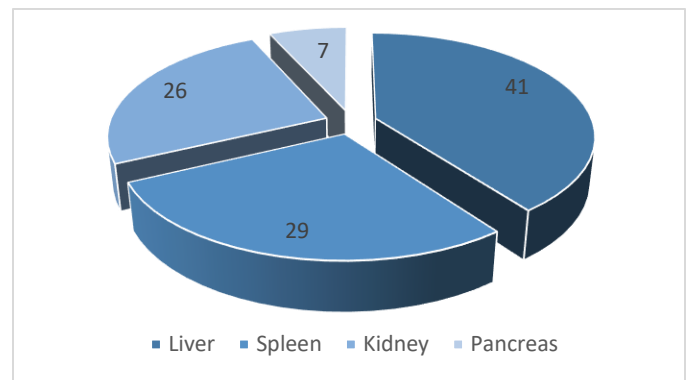
Age Group	Males	Females	Total
4-17	3	0	3
18-25	17	2	19
25-40	15	3	18
>40	9	7	16

Road traffic accidents were most common cause of trauma (58.9%) followed by fall from heights (32.1%). Other causes of injury were due to some sporting accidents (7.1%) or in 1 case (0.18%), due to physical violence. Among the fall from heights, many were children. (Figure 1).



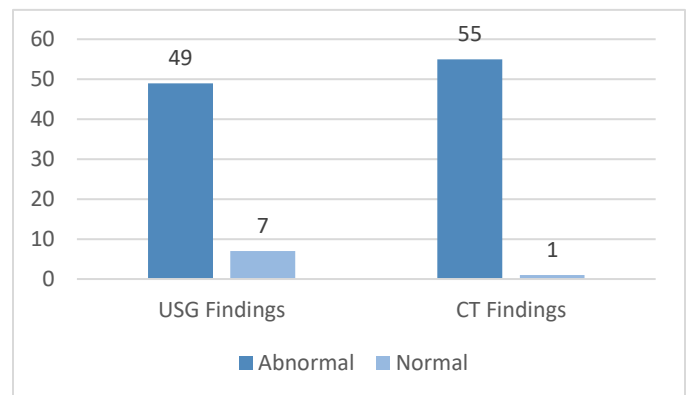
**Figure 1: Causes of trauma**

Liver (73.2%), spleen (51.8%). 46.4% of kidneys and 12.5% of the pancreas were also found to be most commonly affected organs (Figure 2).



**Figure 2: Organs affected**

Out of the 56 patients with blunt abdominal trauma, 49 patients (87.5%) were detected by ultrasound and 7 (12.5%) were missed. However, only 1 case (1.8%) was missed by CT scan, thereby having a sensitivity of 98.2%. p-value <.05 (Figure 3)

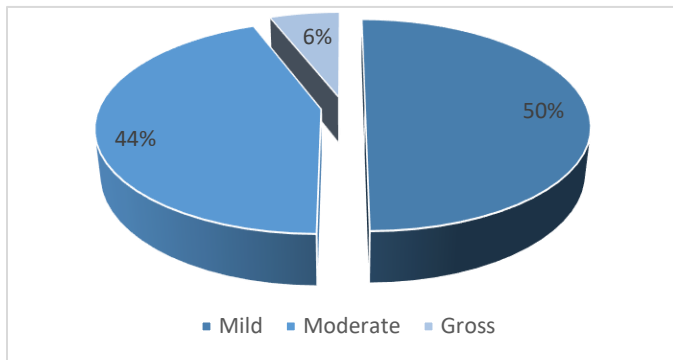


**Figure 3: Comparison of USG and CT values**

Free fluid was correctly identified in all 56 patients (100%) with CT scan while the same was identified only in 47 cases (83.9%) with USG. p value <.01

The quantification of the hemoperitoneum was done by CT in accordance to Salomone et al. The hemoperitoneum was

divided into 3 categories depending on the location and the amount of fluid identified. If the fluid was seen only in one space, it was categorized as mild, with the quantity of the fluid being 100-200ml. If there was fluid in two or more spaces and on the pelvis, with the quantity being 250-500ml, it was classified as moderate and if there was fluid in all the spaces pelvic fluid superior or anterior to the urinary bladder, with fluid quantity exceeding 500ml, it was classified as gross (Figure 4)



**Figure 4: CT quantification of hemoperitoneum**

## DISCUSSION

Road traffic accidents, falls and assaults are responsible for majority of BAT cases and intra-abdominal injuries are very frequent. Liver, spleen, kidney and hollow viscera are most commonly injured organs. In some cases, colo rectal (4%-15%) injuries have also been seen<sup>6</sup>

Visceral injuries are important to diagnose because they cannot be managed conservatively and all patients need to undergo exploration. The morbidity of intra-abdominal perforations is directly related to delayed diagnosis. FAST scan cannot pick up subtle findings of gut and mesenteric injuries<sup>7</sup>

Early detection of these life-threatening injuries is important to initiate appropriate management protocols. The use of FAST and CT scan has replaced conventional methods. FAST scan was introduced in early 1990's. It consists of a focused assessment of abdominal cavity and pericardium. Various studies have shown sensitivity and specificity of FAST to be around 63-100% and 95-100% respectively.<sup>8</sup>

In the present study, the age group which was mostly affected was between 18-40 years. This is probably because this age group normally leads an active life outdoors. People around 50 years have a lesser active life outdoors. However, this age was not a significant aspect for occurrence of abdominal trauma. Neither was the gender. Males are normally active outdoors, and susceptible to accidents compared to the women. In present study, 49 out of 56 cases of abdominal trauma was detected with USG and 7 cases were missed out, 6 of which were detected by CT scan. Lower sensitivity of FAST can be due to Bowel gas, subcutaneous emphysema, and obesity which represent common obstacles to full ultrasound. The volume of free fluid necessary to enable detection with FAST also represents a limitation of FAST. Branney and colleagues determined that the mean minimum detectable free-fluid volume

during FAST examination in 100 patients undergoing DPL was 619 mL in the Morison pouch.<sup>9</sup>

The most common organ to be affected during the blunt abdominal trauma in present study was the liver, followed by spleen, kidney and pancreas. In hemodynamically stable patients CT scan of abdomen is an appropriate investigation for diagnosis and grading of liver injury.<sup>10</sup> Multidetector CT scan has excellent role in detecting transaction injuries of small bowel.<sup>11</sup> The hemoperitoneum was identified in all the cases with CT scan, while only 47 cases were identified with USG in our study. In a study by Vadodariya et al, similar results were observed where the authors reported CT scan is a better diagnostic tool as compared to FAST scan. Unnecessary emergency explorations can be avoided in the presence of a negative scan.<sup>12</sup>

Although USG and CT scan have replaced most of the older diagnostic procedures for the detection of BAT, apart from many advantages, both of these procedures have their disadvantages. Various studies suggest false negative results are rare with ultrasound (1%). FAST scan cannot detect retroperitoneal injuries and diaphragmatic rupture.<sup>7</sup> CT on the other hand, requires experienced personnel and is not a suitable diagnostic approach in hemodynamically unstable patients. Also, radiation risks and contrast related concerns can delay or limit CT evaluation in some patients.<sup>5</sup>

## CONCLUSION



CT scan is a superior imaging tool for the detection of BAT compared to USG. Although USG is also a very valuable tool, it can miss some of the crucial injuries which need immediate attention for the life of the patient. It is therefore recommended that if the patient is stable, all USG should be followed by CT scans.

## REFERENCES

1. Feyzi A, Rad MP, Ahanchi N, Firoozabadi J. Diagnostic accuracy of ultrasonography in detection of blunt abdominal trauma and comparison of early and late ultrasonography 24 hours after trauma. *Pak J Med Sci.* 2015;31(4):980-3.
2. Neeki MM, Hendy D, Dong F, Toy J, Jones K, Kuhnen K, et al. Correlating abdominal pain and intra-abdominal injury in patients with blunt abdominal trauma. *Trauma Surg Acute Care Open* 2017;2:1-7.
3. Kendall J, Kestler A, Whitaker K, Adkisson M-M, Haukoos J. Blunt Abdominal Trauma Patients Are at Very Low Risk for Intra-Abdominal Injury after Emergency Department Observation. *West J Emerg Med.* 2011;12(4):496-04.
4. Elbaih AH, Abu-Elela ST. Predictive value of focused assessment with sonography for trauma (FAST) for laparotomy in unstable polytrauma Egyptians patients. *Chin J Traumatol.* 2017;20(6):323-8.
5. Waheed KB, Baig AA, Raza A, Ul Hassan MZ, Khattab MA, Raza U. Diagnostic accuracy of Focused Assessment with Sonography for Trauma for blunt abdominal trauma in the Eastern Region of Saudi Arabia. *Saudi Med J.* 2018;39(6):598-02.

6. Aboobakar MR, Singh JP, Maharaj K, Mewa Kinoo S, Singh B. Gastric perforation following blunt abdominal trauma. Trauma Case Rep. 2017;10(3):12-5.
7. Mohammadi A, Ghasemi-Rad M. Evaluation of gastrointestinal injury in blunt abdominal trauma "FAST is not reliable": the role of repeated ultrasonography. World J Emerg Surg. 2012;7(1):2-9.
8. Weile J, Nielsen K, Primdahl SC, Frederiksen CA, Laursen CB, Sloth E, Kirkegaard H. Ultrasonography in trauma: a nation-wide cross-sectional investigation. Crit Ultrasound J. 2017;9(1):16-9.
9. Richards JR, Mcgahan JP. Focused Assessment with Sonography in Trauma (FAST) in 2017: What Radiologists Can Learn. Radiology. 2017;283(1):30-48.
10. Afifi I, Abayazeed S, El-Menyar A, Abdelrahman H, Peralta R, Al-Thani H. Blunt liver trauma: a descriptive analysis from a level I trauma center. BMC Surg. 2018;18(1):42-9.
11. Mehta C, Shingade RG, Patel J, Parmar G. Isolated complete jejunal transection after blunt abdominal trauma: CT Imaging. J Clin Diagn Res. 2016;10(3):5-6.
12. Vadodariya K, Hathila VP, Mehta K. The role of computed tomography in management of blunt abdominal trauma conducted at Government tertiary hospital, Western India: A prospective observational study. Int J Sci Res. 2014;3(2):368-70.

### **AUTHORSHIP AND CONTRIBUTION DECLARATION**

AUTHORS	Contribution to The Paper	Signatures
<b>Dr. Ata Ul Lateef</b> Associate Professor Surgery Faisalabad Medical University, Faisalabad	Carried out the Research and Wrote the Article	
<b>Dr. Asrar Ahmad Khan</b> Assistant Professor Surgery Faisalabad Medical University, Faisalabad	Assisted in Research and Proof Reading	
<b>Dr. Maham Mansoor Rana</b> Post Graduate Resident Year 3 Surgical Unit 1 Allied Hospital Faisalabad	Composed the article and arrange the References	