

Neurosurgical Approaches and Visual Outcomes in Pituitary Adenoma Surgery

Pir Tufail Ahmad¹, Ihsanullah², Mohammad Nasir³, Fayyaz Ahmad⁴, Rizwan Ali⁵

- ¹ Specialist Registrar, Department of Neurosurgery, Hayatabad Medical Complex, Peshawar Pakistan
Conceptualization, Data analysis, Writing – Review & Editing
- ² Assistant Professor, Department of Neurosurgery, MTI-Lady Reading Hospital, Peshawar Pakistan
Investigation, Data collection, Formal analysis
- ³ Specialist Registrar, Department of Neurosurgery, Hayatabad Medical Complex, Peshawar Pakistan
Methodology, Data Collection, Writing – Original draft
- ⁴ Specialist Registrar, Department of Neurosurgery, MTI-Hayatabad Medical Complex Peshawar Pakistan
Supervision, Writing – Review & Editing
- ⁵ Specialist Registrar, Department of Neurosurgery, MTI-Mardan Medical Complex, Mardan Pakistan
Methodology, Writing – Review & Editing, Project administration

CORRESPONDING AUTHOR

Dr. Mohammad Nasir
Specialist Registrar, Department of Neurosurgery,
Hayatabad Medical Complex, Peshawar Pakistan
Email: drnasir743@gmail.com

Submitted for Publication: 05-03-2025
Accepted for Publication 20-06-2025

How to Cite: Ahmad PT, Nasir M, Ihsanullah, Ahmad F, Ali R. Neurosurgical Approaches and Visual Outcomes in Pituitary Adenoma Surgery. APMC 2025;19(2):73-77. DOI: 10.29054/APMC/2025.1738

ABSTRACT

Objective: To evaluate the visual outcomes of patients undergoing pituitary adenoma surgery using transsphenoidal and transcranial approaches at Hayatabad Medical Complex, Peshawar. The study focused on identifying factors influencing visual recovery and comparing the effectiveness of both surgical methods. **Study Design:** retrospective study. **Settings:** Department of Neurosurgery, Hayatabad Medical Complex, Peshawar Pakistan. **Duration:** from January 2023 to December 2023. **Methods:** 100 patients divided into two groups: transsphenoidal (n = 50) and transcranial (n = 50). Patient demographics, tumour characteristics, and visual outcomes were analysed. Statistical analysis included chi-square tests, independent t-tests, and logistic regression, with a significance level of $p < 0.05$. **Results:** The mean age of patients was 45.2 ± 13.4 years (transsphenoidal) and 47.6 ± 14.3 years (transcranial) ($p = 0.421$). Preoperative visual acuity was $20/200 \pm 70$ in the transsphenoidal group and $20/180 \pm 65$ in the transcranial group ($p = 0.325$). Postoperatively, visual acuity improved to $20/50 \pm 30$ (transsphenoidal) and $20/100 \pm 55$ (transcranial) ($p = 0.005$). Optic chiasm involvement was significantly higher in the transcranial group (80% vs. 10%, $p < 0.001$). Logistic regression analysis identified the surgical approach as a significant predictor of visual improvement (OR: 2.13, 95% CI: 1.10-4.12, $p = 0.028$). **Conclusion:** Transsphenoidal surgery resulted in better visual outcomes than transcranial surgery. Tumour size and optic chiasm involvement significantly influenced recovery. Future research should focus on long-term outcomes and the development of patient selection criteria.

Keywords: Pituitary adenoma, Transsphenoidal surgery, Visual outcomes, Optic chiasm, Neurosurgery.

INTRODUCTION

Pituitary adenomas are common intracranial neoplasms that account for approximately 10-15% of all brain tumours, with potential consequences including visual impairment, endocrine dysfunction, and neurological deficits.¹ Neurosurgical interventions, particularly transsphenoidal and transcranial approaches, have undergone significant evolution over the years, enhancing surgical precision and patient outcomes.²

Pituitary adenomas are benign tumours originating from the anterior pituitary gland, classified as functioning or non-functioning based on hormone secretion. Functioning adenomas secrete hormones such as prolactin, growth hormone, and adrenocorticotrophic

hormone, leading to clinical syndromes.³ Non-functioning adenomas often remain undiagnosed until they cause mass effects, including visual impairment due to compression of the optic chiasm.⁴

The choice of surgical approach depends on tumour size, location, and extension. The transsphenoidal approach is widely preferred due to its minimally invasive nature, reduced morbidity, and superior visual recovery rates.⁵ In contrast, transcranial approaches are reserved for tumours with extensive suprasellar extension, cavernous sinus invasion, or atypical anatomy.⁶

Several studies have reported favourable visual outcomes following pituitary adenoma surgery. For instance, a study from Nigeria found that 82% of patients presented with visual impairment, and 39.2% showed significant

improvement postoperatively.³ Similarly, research from Pakistan highlighted significant improvements in visual function following transsphenoidal adenoma resection.⁷

Predictors of visual recovery include preoperative visual acuity, tumour size, and surgical extent of resection. A systematic review emphasised that transsphenoidal approaches provide superior visual recovery with lower complication rates than transcranial surgeries.⁸ However, factors such as optic atrophy and prolonged tumour compression negatively impact postoperative visual outcomes.⁹

The rationale for the study stems from the limited data on visual outcomes following pituitary adenoma surgery in Pakistan. While global studies provide valuable insights, regional differences in healthcare infrastructure, surgical expertise, and patient demographics necessitate local research. This study aims to fill the gap by analysing visual outcomes in patients undergoing pituitary adenoma surgery and evaluating neurosurgical approaches and their impact on visual outcomes in these patients.

METHODS

This retrospective study was conducted at the Department of Neurosurgery, Hayatabad Medical Complex, Peshawar, from January 2023 to December 2023 (Ref# 2202, dated 10-11-2022).

The WHO sample size calculation technique was used to calculate the sample size. Based on a previous study, which reported a 62.07% improvement in visual outcomes after pituitary adenoma surgery, with a 95% confidence level and a 5% margin of error, the necessary sample size was determined to be 100 patients. The study included two groups: the transsphenoidal approach (n = 50) and the transcranial approach (n = 50).

Patients diagnosed with pituitary adenoma and who had surgical intervention throughout the research period were included. The inclusion criteria consisted of patients aged 18-75 years, those with radiologically confirmed pituitary adenomas causing visual impairment, and those who had completed at least three months of postoperative follow-up. Patients with recurrent pituitary adenomas, those undergoing reoperation, individuals with severe systemic illnesses, and those with incomplete follow-up data were excluded.

Patient data were extracted from hospital records, including demographic details, clinical presentations, surgical approach, and preoperative and postoperative visual assessments. Visual function was assessed using standard ophthalmological tests, including visual acuity, visual field testing, and Optical Coherence Tomography

(OCT). Tumour characteristics, extent of resection, and complications were also recorded.

Visual outcomes were assessed based on improvements in visual acuity and the resolution of visual field defects postoperatively. The degree of tumour excision was categorised as Gross Total excision (GTR), Subtotal Resection (STR), and Partial Resection (PR) according to post-operative MRI results. Post-operative complications such as Cerebrospinal Fluid (CSF) leaks, hypopituitarism, and infections were also documented.

Data were analysed using SPSS version 25.0. Categorical variables were assessed using the Chi-square test, whilst continuous variables were evaluated using an independent t-test. A p-value of less than 0.05 was deemed statistically significant. Logistic regression analysis was used to determine the determinants of visual enhancement.

The Ethical and Research Committee of Hayatabad Medical Complex, Peshawar, accepted the research—the anonymisation of documents preserved patient confidentiality. Due to the retroactive nature of the data acquisition, informed consent was not necessary.

RESULTS

A total of 100 patients were included in the study, with 50 assigned to the transcranial group and 50 to the transsphenoidal group. In the transcranial group, the mean age was 47.6 ± 14.3 years, whereas in the transsphenoidal group, it was 45.2 ± 13.4 years. Gender distribution was similar across both groups. Preoperative visual acuity in the transsphenoidal group was $20/200 \pm 70$, and in the transcranial group, it was $20/180 \pm 65$ ($p = 0.325$).

Table 1 displays the patient demographics, including age, gender, and preoperative visual acuity. There were no significant differences in age, gender, or visual acuity between the groups (p -values 0.421 and 0.756, respectively).

Table 1: Patient Demographics

Demographic Characteristic	Trans-sphenoidal Group (n=50)	Transcranial Group (n=50)	p-value
Age (mean \pm SD)	45.2 \pm 13.4	47.6 \pm 14.3	0.421
Gender (M/F)	28/22	30/20	0.756
Ethnicity (Pashtun)	50	50	1.000
Preoperative Visual Acuity (mean \pm SD)	20/200 \pm 70	20/180 \pm 65	0.325

Tumour Characteristics and Surgical Approach

With a mean tumour size of 4.2 ± 2.3 cm in the transcranial group—far greater than the 2.5 ± 1.2 cm in the trans-

sphenoidal group— $p = 0.001$. The transcranial group (80% vs. 10%, $p = 0.001$) showed more frequent involvement of optic chiasm. (Table 2)

Table 2: Tumor characteristics

Tumour Characteristics	Trans-sphenoidal Group (n=50)	Transcranial Group (n=50)	p-value
Tumour Size (mean \pm SD, cm)	2.5 \pm 1.2	4.2 \pm 2.3	0.001
Optic Chiasm Involvement	5	40	<0.001

Visual Outcomes: Preoperative vs Post-operative Visual Acuity

Post-operative visual acuity improved significantly in both groups. In the trans-sphenoidal group, visual acuity improved from 20/200 \pm 70 preoperatively to 20/50 \pm 30 postoperatively. In the transcranial group, visual acuity improved from 20/180 \pm 65 to 20/100 \pm 55. The improvement was significant in both groups ($p = 0.005$), with 85% of patients in the trans-sphenoidal group showing improvement compared to 75% in the transcranial group ($p = 0.122$). Table 3 shows the change in visual acuity preoperatively and postoperatively in both groups.

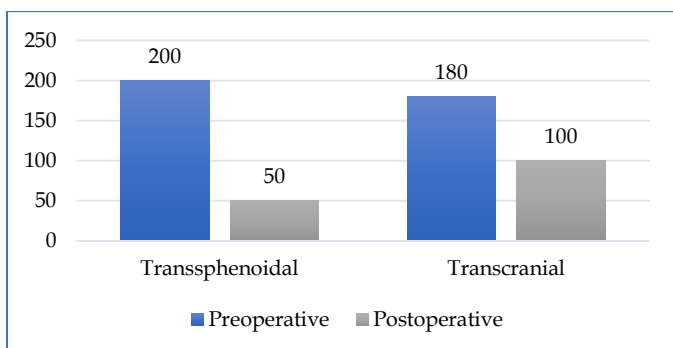
Table 3: Preoperative and post-operative visual acuity

Visual Acuity (Snellen)	Trans-sphenoidal Group (n=50)	Transcranial Group (n=50)	p-value
Preoperative	20/200 \pm 70	20/180 \pm 65	0.325
Post-operative	20/50 \pm 30	20/100 \pm 55	0.005
Improvement (%)	85%	75%	0.122

Post-operative Visual Field Defects

The transsphenoidal group showed greater resolution of visual field defects compared to the transcranial group. Figure 1 shows a significant reduction in visual field defects post-surgery for the transsphenoidal group, while the transcranial group showed moderate improvement with partial remaining defects.

Figure 1: Change in visual acuity preoperatively and postoperatively



Statistical Analysis

Logistic regression analysis revealed that the surgical approach was a significant predictor of visual improvement (odds ratio, 2.13; 95% CI, 1.10-4.12; $p = 0.028$). Tumour size approached significance ($p = 0.074$), indicating it may impact visual recovery.

Table 4: Logistic Regression Analysis for Predictors of Visual Improvement

Predictor	Odds Ratio (OR)	95% CI	p-value
Surgical Approach (Trans-sphenoidal)	2.13	1.10 - 4.12	0.028
Age	0.98	0.95 - 1.01	0.215
Tumour Size	0.87	0.76 - 1.01	0.074

DISCUSSION

This study demonstrated that both transsphenoidal and transcranial surgical approaches led to significant visual improvement in patients with pituitary adenomas, with a greater degree of improvement observed in the transsphenoidal group. The statistical analysis revealed that the transsphenoidal approach had a higher likelihood of improving visual outcomes, with an odds ratio of 2.13 ($p = 0.028$). Additionally, tumour size and optic chiasm involvement played a crucial role in determining surgical success. These findings align with previous international studies but also highlight specific regional differences that merit further exploration.

The present study adds to the growing body of knowledge on pituitary adenoma surgery by focusing on a Pakistani patient population at Hayatabad Medical Complex, Peshawar. Previous studies have primarily centred on Western and East Asian cohorts, making this study a valuable contribution to regional literature.¹

Several international studies have reported similar findings, particularly regarding the superiority of transsphenoidal surgery in preserving and enhancing visual function.⁴ However, a gap remains in research focused on Pakistani patients, particularly in terms of long-term outcomes and comparisons across various healthcare settings.

Studies from countries such as the United States, Thailand, and Nigeria have emphasised the benefits of early surgical intervention in improving visual prognosis.² Research in Thailand found that visual improvement was significantly associated with early intervention, a finding that is echoed in our study. Moreover, studies from Nigeria and Russia also support the notion that tumour

size and optic chiasm involvement significantly impact surgical outcomes.³

Despite these similarities, there is a notable lack of extensive research within Pakistan that addresses these aspects. While some Pakistani studies have reported on pituitary adenoma surgery, they have primarily focused on endocrinological outcomes rather than visual improvement.⁷

A systematic review comparing transcranial and transsphenoidal approaches indicated that the latter results in fewer complications and better visual recovery rates.⁸ Our study corroborates these findings, as transsphenoidal surgery demonstrated superior visual outcomes. However, one limitation in the existing literature is the variability in surgical expertise and post-operative care, which significantly influences results.

Moreover, research conducted in high-resource settings, such as Europe and North America, may not be entirely generalizable to developing nations where healthcare infrastructure varies significantly.⁹ Our study emphasises the need for further localised research that considers socio-economic and healthcare-related disparities in Pakistan.

FUTURE DIRECTIONS

Future research should explore the long-term visual and endocrinological outcomes of pituitary adenoma surgery in Pakistan. A prospective study design with a larger sample size and longer follow-up would provide a more comprehensive understanding of patient outcomes. Additionally, comparative studies evaluating surgical expertise, post-operative care, and rehabilitation strategies between high-income and low-income settings would offer valuable insights. Incorporating machine learning models for preoperative prediction of visual outcomes based on MRI findings could also significantly enhance surgical planning and patient counselling.¹¹

LIMITATIONS

This study has various limitations. First of all, it is inherently prone to selection bias due to its retrospective nature. Second, the follow-up period, which was only 12 months, may not be sufficient to evaluate long-term results. Another limitation is the lack of detailed hormonal assessment data, which could have provided additional insights into patient recovery. Future studies should aim for longer follow-up durations and incorporate multicentre data to improve generalizability.

CONCLUSION

This study assessed the impact of neurosurgical approaches on visual outcomes in patients undergoing surgery for pituitary adenomas. The findings

demonstrate that the transsphenoidal approach resulted in superior visual recovery compared to the transcranial approach, with a higher percentage of patients experiencing significant post-operative visual improvement. The study also confirmed that tumour size and optic chiasm involvement were critical factors influencing surgical success.

The study successfully met its objective of assessing visual outcomes in pituitary adenoma surgeries. Statistical analysis supported the conclusion that the transsphenoidal approach is preferable in terms of visual prognosis. The results align with existing literature and provide new insights into patient outcomes in a Pakistani healthcare setting.

Transsphenoidal surgery is an effective intervention for preserving and improving visual function in pituitary adenoma patients. The surgical approach plays a vital role in determining post-operative success, emphasising the importance of early intervention and careful patient selection.

SUGGESTIONS / RECOMMENDATIONS

Future research should focus on long-term follow-up studies to evaluate sustained visual improvements and potential complications. Prospective multicentre studies with larger sample sizes are needed to validate these findings further. Additionally, incorporating advanced imaging techniques and predictive models may enhance preoperative planning and optimise patient outcomes.

CONFLICT OF INTEREST / DISCLOSURE

The authors declare that there are no conflicts of interest regarding the publication of this manuscript.

ACKNOWLEDGEMENTS

The authors would like to express their gratitude to the staff and medical team at Hayatabad Medical Complex, Peshawar, for their invaluable assistance in data collection and patient management. We also acknowledge the contributions of the patients who participated in the study.

REFERENCES

1. Chibbaro S, Signorelli F, Milani D, Cebula H, Scibilia A, Bozzi MT, et al. Primary Endoscopic Endonasal Management of Giant Pituitary Adenomas: Outcome and Pitfalls from a Large Prospective Multicenter Experience. *Cancers (Basel)*. 2021 Jul 18;13(14):3603.
2. Shen M, Chen Z, Shou X, Ma Z, Ye Z, He W, et al. Surgical Outcomes and Predictors of Visual Function Alterations After Transcranial Surgery for Large-to-Giant Pituitary Adenomas. *World Neurosurg*. 2020 Sep;141:e60-e69.
3. Charles U, Anthony A, Emeka N, Cyril O, Obinna A, Morayo S, Obasi E, Shola J, Jibril P, Chinedu A, Folusho A. Visual and endocrine outcome following surgery for pituitary adenoma in a

- tertiary hospital, North Central Nigeria. *Br J Neurosurg.* 2024 Jun;38(3):639-642.
4. Kemchoknatee P, Singhakul C, Arjkongharn N, Vongsa N, Tangon D, Srisombut T. Insights into Visual Outcomes and Determinants in Pituitary Adenoma Surgery: A 5-Year Retrospective Cohort Study. *Clin Ophthalmol.* 2024 Jun 21;18:1779-1788.
 5. Castle-Kirszbaum M, Wang YY, King J, Goldschlager T. Predictors of visual and endocrine outcomes after endoscopic transsphenoidal surgery for pituitary adenomas. *Neurosurg Rev.* 2022 Feb;45(1):843-853.
 6. Jang H, Im YH, Kim DH, Chung DS, Yoon WS. Hurdle of giant pituitary adenoma in achieving total resection. *Journal of Korean Skull Base Society.* 2023 Oct 31;18(2):113-22.
 7. Khan N, Ali W. Quantitative Assessment of Visual Field Recovery Following Transsphenoidal Pituitary Adenoma Excision and its Time Course. *Journal of Health and Rehabilitation Research.* 2024 May 26;4(2):957-62.
 8. Toader C, Bratu BG, Mohan AG, Bentia D, Ciurea AV. Comparison of Transcranial and Transsphenoidal Approaches In Intra And Suprasellar Pituitary Adenomas - Systematic Review. *Acta Endocrinol (Buchar).* 2023 Apr-Jun;19(2):228-233.
 9. Ito M, Suda K, Nakano E, Tagawa M, Miyata M, Kashii S, et al. Influence of Tumor Characteristics on Visual Field Outcomes After Pituitary Adenoma Surgery. *J Neuroophthalmol.* 2023 Sep 1;43(3):376-382.
 10. Nath HD, Razib KO, Halder R, Rahman MA, Hasan MM, Uddin AN, et al. Outcome of Pituitary Adenoma Surgery Through Transphenoidal Endoscopic Endonasal Approach-A Study of 96 Cases. *Bangladesh Journal of Neurosurgery.* 2023;13(1):29-33.
 11. Zhang Y. Fully Automated Approach to Predict the Visual Outcome After Pituitary Adenoma Surgery Based On Preoperative Mri Using Deep Learning. In-*Neuro-Oncology* 2024 Oct 17 (Vol. 26, pp. V60-V60). Journals Dept, 2001 Evans RD, Cary, NC 27513 USA: OXFORD UNIV PRESS INC.