

# Comparison between the Efficacy of Conservative Management and Ultrasound Guided Pigtail Catheter Drainage of Uncomplicated Amoebic Liver Abscess

Anum Nawazish Ali<sup>1</sup>, Rabia Aftab<sup>2</sup>, Muhammad Awais Nazir<sup>3</sup>, Natasha Sheheryar<sup>4</sup>, Mansoor Ahmad<sup>5</sup>, Nazia Arain<sup>6</sup>

<sup>1</sup> MS in Health Administration, Surgical Technologist, King Edward Medical University, Mayo Hospital, Lahore Pakistan  
Data collection, Perform experimental work, Paper writing

<sup>2</sup> House Officer, Department of ENT, Shaikh Zayed Hospital, Lahore Pakistan  
Data collection, Result analysis

<sup>3</sup> House Officer, Department of Pulmonology, Shaikh Zayed Hospital, Lahore Pakistan  
Compiled the paper

<sup>4</sup> Visiting Faculty Member, Department of Radiology, Bahria University Medical & Dental College, Karachi, Pakistan  
Data analysis, Review the paper

<sup>5</sup> House Officer, Department of Diagnostic Radiology, Shaikh Zayed Hospital, Lahore Pakistan  
Data analysis, Sample collection

<sup>6</sup> Registrar at PMCH Nawabshah Medical Unit 1 PMC Hospital, Nawabshah Pakistan  
References write up

## CORRESPONDING AUTHOR

Dr. Anum Nawazish Ali  
MS in Health Administration, Surgical Technologist, King Edward Medical University, Mayo Hospital, Lahore Pakistan  
Email: dr.anamali1@gmail.com

Submitted for Publication: 29-12-2021  
Accepted for Publication 26-04-2022

**How to Cite:** Ali AN, Aftab R, Nazir MA, Sheheryar N, Ahmad M, Arain N. Comparison between the Efficacy of Conservative Management and Ultrasound Guided Pigtail Catheter Drainage of Uncomplicated Amoebic Liver Abscess. APMC 2022;16(2):108-112. DOI: 10.29054/APMC/2022.1348

## ABSTRACT

**Background:** Fever and pain in the upper right quadrant of the body almost often indicate a liver abscess. A lot of people in the tropics become sick from it. An abscess in the liver can be caused by either amoeba or bacteria, and these two types are known as pyogenic and amoebic, respectively. **Objective:** To compare the efficacy of conservative management and ultrasound guided pigtail drainage of amoebic liver abscess. **Study Design:** This study used retrospective analytical design. **Settings:** The study was carried out at Shaikh Zayed Hospital, Lahore. **Duration:** Twelve months from July 2020 to July 2021. **Methods:** Total 40 patients were split into two research groups conservative management & pigtail catheter drainage group. Patients with simple cases of ALA were sought for participation. Pharmaceutical treatment was the first line of defense for all patients for the first 72 hours. The patients were chosen using a method of convenient allocation. Estimation of the sample size was also performed conveniently. **Results:** There were 38 men (95%) and 2 women (5%), in all. There were 20 males in group 2 and 18 males in group 1 of the study group. Patients admitted to the hospital for the study reported an average VAS of pain of 6.02 ±2.75. At 72 hours, the mean visual analogue scale (VAS) score for pain in the study population was 1.68 2.786. There was a statistically significant difference [P<0.001] of 4.35 on the VAS between admission and 72 hours. **Conclusion:** The results of our study show that draining an Amoebic liver abscess using a pigtail catheter is more effective than conservative treatment for the resolution of a single, uncomplicated liver abscess in the right lobe, in patients whose abscess measured between 6.0 and 10.0 centimeters in size.

**Keywords:** Conservative management, Pigtail catheter, Drainage, Amoebic liver abscess.

## INTRODUCTION

Hepatic abscess is a pus-filled mass in the liver caused by a liver injury or an infection that spread from the abdominal cavity into the portal vein.<sup>1</sup> Since the liver receives blood from the system and portal circulations, infections and bloodborne pathogens are both possible causes.<sup>2</sup> The most common extra intestinal form of amoebiasis is amoebic liver abscess (ALA), which is extremely prevalent in subcontinent.<sup>3</sup> Infection with *Entamoeba histolytica* is associated with ALA in 3-9% of patients. "Dysenteries, when they set in with fever and

alvine discharges of a heterogeneous character, or with inflammation of liver are dangerous".<sup>4</sup>

Leakage of intestinal contents, appendicitis, cholangitis and peritonitis are all possible causes of liver abscesses. Suppurative liver lesions are caused by a wide range of microorganisms and are classified as either fungal or bacterial liver abscess, or amoebic liver abscess.<sup>5,6</sup> Liver abscesses caused by bacteria are the most common kind, while *Staphylococcus aureus* and *E. coli* are the most common causative microorganisms. Untreated,

this condition carries a 10%-30% mortality rate due to the systemic toxic diseases it might trigger.<sup>7</sup>

Liver abscesses are often misdiagnosed in the early stages because their clinical features are not very distinct from other conditions. The fast escalation of septic shock into organ failure and mortality is triggered by missed opportunities for early detection and treatment. Researchers found that septic shock affects 16% of patients with liver abscesses, and 2.2% of those individuals ultimately succumb to it.<sup>8</sup> Currently, percutaneous transhepatic puncture and drainage along with broad-spectrum antibiotics are the gold standard for treating liver abscesses. However, there is a risk that patients will develop drug resistance while taking broad-spectrum antibiotics.<sup>9</sup>

Literature research shows that one or several minor Amoebic liver abscesses can be treated using non-invasive methods. Closed or open drainage is necessary for larger Amoebic liver abscesses or those with consequences (pre-rupture, rupture, pressure effects). Treatment options for simple, symptomatic, medium-sized Amoebic liver abscesses range from medicines alone to needle aspiration and pigtail catheter drainage, and there is no clear-cut consensus for their care. The purpose of the current research is to provide a universally applicable standard for treating such abscesses. By determining the most effective treatment strategy in relation to disease severity, this research can help cut down on health problems caused by the illness. Mortality and disability from the disease could be reduced with better management.

## METHODS

This research was conducted in Shaikh Zayed Hospital, Lahore and used an analytical retrospective approach. Researchers gathered data from July 2020 to July 2021. From our institute's computerized patient management system, data of 40 patients with a confirmed liver abscess diagnosis were taken.

Abscess sizes less than 10 cm in patients with amoebic liver abscess were included in this study. Patients experiencing severe abscess symptoms (rupture, pressure, etc.), an abscess that is larger than 10 centimeters in size and individuals whose INR is >1.5 were excluded. In this study, patients are divided at random between two groups. In group I Antiamoebic (for ten days, use metronidazole 500 mg three times a day) and antibiotic medications (4.5 gm of piperacillin and tazobactam twice daily for 10 days) were administered to patients in this group. In addition to standard medical care, patients in this cohort underwent indwelling pigtail catheter drainage guided by ultrasound in group II patients.

Participants in the study were given a comprehensive medical history (which included questions about alcohol use) and a thorough physical examination. Complete blood count, coagulation profile (PT/INR), liver function test, abdominal ultrasound, chest x-ray, biopsy, culture of aspirated pus, and other tests may be necessary (Group II).

Patients were monitored on a daily basis to assess their clinical status. The criteria for sustaining a certain modality of treatment were changes for the better in pain (VAS) within 72 hours.

Patients were split into two groups of 50, with Study Group II undergoing ultrasound-guided pigtail catheterization following informed agreement. Wet mount inspection for *Entamoeba histolytica* trophozoites, Sensitivity, Gram's staining, and pus culture were performed on the collected output before it was sent off for further analysis. Daily charting of catheter outflow was performed and kept.

Quantitative measures total lymphocyte count (TLC), length of hospital stay was used to determine the outcome. The patient's prognosis was checked again after 72 hours. If the patient did not improve after the first therapy, they underwent the second treatment, which was a transition from conservative care to open drainage.

The study's patients were admitted to the care of a single surgical team that had extensive experience with both general and hepatobiliary surgery.

SPSS version 22.0 was used for data compilation and statistical analysis. Mean and standard deviation were used to show the continuous quantitative values (or median and range as appropriate). Frequency and percentages for nominal and ordinal categorical variables were shown in a tabulated form. The tests of significance used for the appropriate comparison were the Chi-square test for qualitative variables and the student's t-test for quantitative variables, with a significance level of P 0.05 being considered to indicate statistical significance.

## RESULTS

The age range for Group I is 22 to 56 with a mean of 37.6 years, and for Group II it is 39.8 years. In the case group (n = 40), the male to female ratio was 5:1. There were 38 men (95%) and 2 women (5%), in all. There were 20 males in group 2 and 18 males in group 1 of the study group. While there were two females in group 1 and none in group 2, respectively. Group 1 (n=20) had an average of 13.45 days before presenting symptoms, while Group 2 (n=20) had an average of 17.20 days. Seventy-percent of the cases in the case group had a previous history of alcohol consumption, found in 14 out of 20 cases. Eleven out of twenty patients (55%) in the study group reported

a previous history of alcohol consumption. In 31 of 40 (77.5%) patients, the amoebic serology was positive. Positive results for amoebic serology were found in 16 of the cases (80%) in group 1 and 15 of the cases (75%) in group 2. Study group1 had a mean serum bilirubin level of 0.55 mg/dl (range, 0.4-0.9 mg/dl). Serum bilirubin levels in Group 2 averaged 0.94 mg/dl (range, 0.4-1.4 mg/dl). Values ranged from a high of 1.4mg/dl to a low of 0.4mg/dl as shown in Table 1.

**Table 1: Details of demographics variables f enrolled patients**

Variables	Characteristics	Conservative Management Group-I	Pigtail Drainage Group-II
Age	Mean ± SD	37.6 years	39.8 years
Gender	Male	2 (100.0)	0 (0.0)
	Female	18 (47.4)	20 (52.6)
	≤5	8 (40.0)	2 (10.0)
	≥21	0 (0.0)	8 (40.0)
Alcohol intake	Yes	6 (30.0)	9 (45.0)
	No	14 (70.0)	11 (55.0)
Amoebic serology	Negative	4 (20.0)	5 (25.0)
	Positive	16 (80.0)	15 (75.0)
Total serum bilirubin	mg/dl	0.55	0.94

Thus, 29 cases (72.5%) involved multiple abscesses while 11 cases (27.5%) involved only a single abscess. Seven (24.2% of the total) of the multiple abscesses were located on the left side, while 22 (75.8%) were located on the right as shown in Table 2.

**Table 2: Distribution along with number of abscesses, side of abscess**

Variables	Characteristics	Conservative Management Group-I	Pigtail Drainage Group-II
Type of abscesses	Multiple	29%	72.5%
	Single	11%	27.5%
Side of abscess	Left	7%	24.2%
	Right	22%	75.8%

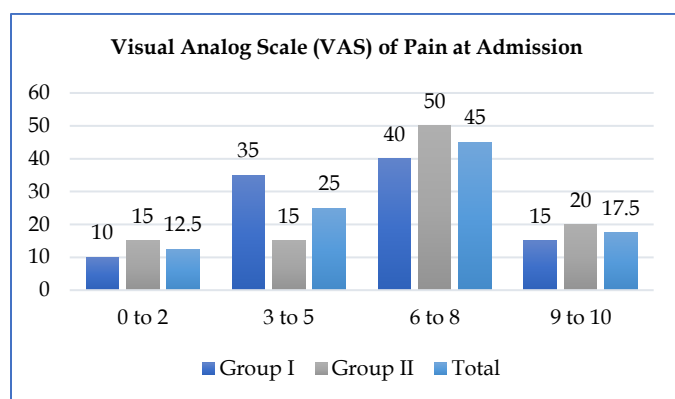
Group-I had a mean maximum diameter of 8.45±0.71, while Group-II's 8.75±0.71 at admission. The mean maximum diameter of the cases was 7.75 ± 0.71, while the mean maximum diameter of the controls was 8.00 ± 0.72 at 72 hour.as shown in Table 3.

**Table 3: Distribution as per Size of ALA & TLC count**

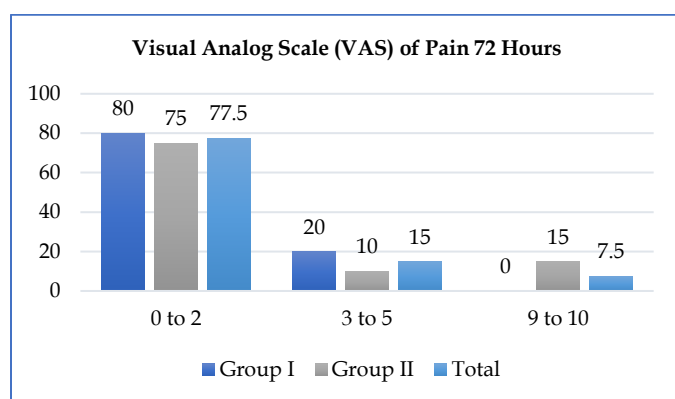
Variables	Characteristics	Conservative Management Group-I	Pigtail Drainage Group-II	P-Value
Size of ALA	Diameter at admission cm	8.45 ±0.71	8.75 ± 0.71	p<0.01
	Diameter at 72 h cm	7.75 ± 0.71	8.00 ± 0.72	
Total Leukocyte Count (TLC)	at admission cell/mm3	13700 ± 5937	6812 ± 6832	p<0.01
	at 72 h cm	6050 ± 5548	9640 ± 3748	

Patients admitted to the hospital for the study reported an average VAS of pain of 6.02 ±2.75. At 72 hours, the mean visual analogue scale (VAS) score for pain in the study population was 1.68 ±2.786. There was a statistically significant difference [P<0.001] of 4.35 on the VAS between admission and 72 hours as shown at graph in Figure 1.

**Figure 1a: Pain score on the visual analog scale (VAS) at admission**



**Figure 1b: Pain score on the Visual Analog Scale (VAS) at 72 hours**



**DISCUSSION**

Here, we compare two methods for treating simple amoebiasis among 40 patients (20 in each of Groups -I and II). Accumulation of pus in the liver Comparing the

outcomes of conservative treatment for a 6.0-10.0cm amoebic liver abscess with those of ultrasound-guided pigtail drainage. The median age of presentation is 40 years and 15 months, which is consistent with the findings of Sharma et al. (2010)<sup>10</sup> and Linda et al. (2014).<sup>11</sup> There is a gender disparity in liver abscess, with more men affected than women. In the current study, males had an 8.1 times higher prevalence of liver abscess than females did.

In this study, Group I patients experienced symptoms for a mean of 13.45 days before seeking medical attention (range 1-60 days). Group II had symptoms for an average of 17.20 days before seeking medical attention. The average duration of symptoms in the acute group was 10 days, according to the studies of Gupta et al., whereas the average duration in the chronic group was 3 years, with a range of 3-6 months.<sup>12</sup> In his study, Salles et al. noted that patients typically sought care within two weeks of the onset of symptoms, though this ranged from four days to twelve weeks for some.<sup>13</sup>

Eighteen out of twenty Group patients tested positive for amoebic serology, or 90%. In Group II, 85.05% of participants tested positive. In patients with amoebic liver abscess, 79.1% had positive amoebic serology, according to studies by Gandhi et al<sup>14</sup> and Lodhi et al<sup>15</sup>. Serological testing can assist assess the risk of invasive amoebas in asymptomatic cyst passers in endemic regions, as these individuals also develop antibodies. Total serum bilirubin averaged 0.55mg/dl in Group -I and 0.94mg/dl in Group II. Lodhi et al<sup>15</sup> and Khanna et al.<sup>16</sup> found that total bilirubin levels averaged 1.9mg/dl.

In the current investigation, thirty cases with multiple abscesses were examined; twenty-five (83%) were associated with the right lobe and five (16%) were associated with the left lobe. According to Gandhi et al.<sup>14</sup> research, 73% of cases of amoebic liver abscess involve the right lobe, 17% involve the left lobe, and 10% involve both lobes.

Because of the streamlining effect—that is, because the portal vein is a straight continuation of the right hemiliver—involvement of the right lobe is more likely. In our investigation, multiple abscesses were more common because of the patients' poor health, lowered immunity, substandard housing, and higher virulence of the implicated organisms. Khan et al,<sup>18</sup> Sharma et al<sup>10</sup> and Linda et al<sup>11</sup> all found outcomes that were consistent with our study's findings.

In Group I, patients spent an average of 6.95 days in the hospital, while in Group II, they spent 17.20 days. Group I is significantly different from Group II at the 0.01% level of significance. The average length of hospitalization for the participants was 7.22 days. According to previous

research, patients could spend anywhere from four to twenty-four days in the hospital.<sup>18</sup> Patients who were treated conservatively, according to another study, had a mean hospital stay of 7.3 days.<sup>19</sup>

Our results show that ALA drainage with a pigtail catheter is superior to conservative management for the early and rapid clearance of simple right lobe liver abscesses measuring 6.0 to 10.0 cm in size. Pigtail insertion under Sonographic guidance was found to be the most effective treatment for simple abscesses ranging in size from 6.0 to 10.0 centimeters in this investigation.

## CONCLUSION

The results of our study show that draining an Amoebic liver abscess using a pigtail catheter is more effective than conservative treatment for the resolution of a single, uncomplicated liver abscess in the right lobe, in patients whose abscess measured between 6.0 and 10.0 centimeters in size.

## LIMITATIONS

This study contains a relatively small number of participants.

## SUGGESTIONS / RECOMMENDATIONS

Large-scale research should be done in future studies.

## CONFLICT OF INTEREST / DISCLOSURE

None.

## ACKNOWLEDGEMENTS

None to declare.

## REFERENCES

- Mischnik A, Kern WV, Thimme R. Pyogenic liver abscess: Changes of Organisms and Consequences for Diagnosis and Therapy. *Deutsche Medizinische Wochenschrift* (1946). 2017 Jul 20;142(14):1067-74.
- Goel V, Jain A, Sharma G, Jhajharia A, Agarwal VK, Ashdhir P, Pokharna R, Chauhan V. Evaluating the efficacy of nitazoxanide in uncomplicated amoebic liver abscess. *Indian Journal of Gastroenterology*. 2021 Jun;40(3):272-80.
- Soni A, Bundela R, Ashdhir P, Pokharna R, Nijhawan S. Burden of alcohol related admissions in the gastroenterology department of a North Indian tertiary care centre. *Trop Gastroenterol*. 2017 Jun 15;38(1):36-41.
- Haider SJ, Tarulli M, McNulty NJ, Hoffer EK. Liver Abscesses: Factors That Influence Outcome of Percutaneous Drainage. *AJR Am J Roentgenol*. 2017;209(1):205-213.
- Czerwonko ME, Huespe P, Bertone S, Pellegrini P, Mazza O, Pekolj J, de Santibañes E, Hyon SH, de Santibañes M. Pyogenic liver abscess: current status and predictive factors for recurrence and mortality of first episodes. *Hpb*. 2016 Dec 1;18(12):1023-30.
- Lai HC, Lin CC, Cheng KS, Kao JT, Chou JW, Peng CY, Lai SW, Chen PC, Sung FC. Increased incidence of gastrointestinal cancers among patients with pyogenic liver abscess: a population-based cohort study. *Gastroenterology*. 2014 Jan 1;146(1):129-37.

7. Fu XB, Chen JY. Application value of contrast-enhanced ultrasound in the diagnosis of hepatic abscess. *China Practical Medical*. 2018;13(35):23-4.
8. Cho H, Lee ES, Lee YS, Kim YJ, Sohn CH, Ahn S, Seo DW, Lee JH, Kim WY, Lim KS. Predictors of septic shock in initially stable patients with pyogenic liver abscess. *Scandinavian journal of gastroenterology*. 2017 May 4;52(5):589-94.
9. Ahmed M, Alam J, Hussain S, Aslam M. Prospective randomized comparative study of percutaneous catheter drainage and percutaneous needle aspiration in the treatment of liver abscess. *ANZ Journal of Surgery*. 2021 Mar;91(3):E86-90.
10. Sharma N, Sharma A, Varma S, Lal A, Singh V. Amoebic liver abscess in the medical emergency of a north Indian hospital. *BMC Res Notes* 2010;3:21.
11. Linda AC, Jorge ES, Panduro A, Laura EM. Amebic liver abscess: A new perspective on the prognosis of patients in an endemic area regional referral center. *J Liver* 2014;3:142
12. Gupta R, Purwar V, Patel V. Liver Abscess Management Based on Ultrasonographic Parameters: Conservative Versus Intervention. *IJSS Journal of Surgery* 2018;4(2):1-5.
13. Salles MJ, Moraes AL, salles CM. Hepatic amebiasis. *Braz J Infect Dis*. 2013;7:1-2.
14. Gandhi BM, Irshad M, Acharya SK, Tandon BN. Amebic liver abscess and circulating immune complexes of *Entamoeba histolytica* proteins. *The American journal of tropical medicine and hygiene*. 2008 Nov 1;39(5):440-4.
15. Lodhi S, Sarwari AR, Muzamil M, Salam A, Smego A, Smego RA. Features distinguishing amoebic from pyogenic liver abscesses: a review of 577 adult cases. *Trop Med Int Health* 2014;9: 718-23.
16. Khanna S, Chaudhary O, Kumar A, Vij JC Experience with aspiration in amoebic liver abscess. Report from an endemic area. *Eur J Clin Microbiol Infect Dis* 2005;24: 428-30.
17. Khan R, Hamid S, Abid S, Jafri W, Abbas Z, Islam M, et al. Predictive factors for early aspiration in liver abscess. *World J Gastroenterol* 2008;14:2089-93.
18. Rajak CL, Gupta S, Jain S, et al. Percutaneous treatment of liver abscesses: needle aspiration versus catheter drainage. *Am J Roentgenol* 2008;170(4):1035-9.
19. Ghosh S, Sharma S, Gadpayle AK, et al. Clinical, laboratory, and management profile in patients of liver abscess from northern India. *J Trop Med*. 2014;2014:142382.