

## Mesenchymal Hamartoma – A Case Report

Nagina Shahzadi<sup>1</sup>, Nadeem Hashmat<sup>2</sup>, Samreen Rizwan<sup>3</sup>, Naureen Kanwal Satti<sup>4</sup>

<sup>1</sup> Assistant Professor, Pediatric Gastroenterology, Children Hospital, Faisalabad Pakistan  
Data collection

<sup>2</sup> Pediatric Consultant, Department of Emergency Medicine, King Abdulaziz University Hospital, Riyadh Saudi Arabia  
Manuscript writing, Data collection

<sup>3</sup> GDPM Student, Queen's Family Health Team, Queen's University, Kingston, Ontario Canada  
Data collection

<sup>4</sup> Pediatrician, King Abdulaziz University Hospital, Riyadh Saudi Arabia  
Proof reading

### CORRESPONDING AUTHOR

**Dr. Nadeem Hashmat**

Pediatric Consultant, Department of Emergency Medicine, King Abdulaziz University Hospital, Riyadh Saudi Arabia  
Email: nhashmat17@gmail.com

Submitted for Publication: 11-03-2021  
Accepted for Publication 15-07-2021

**How to Cite:** Shahzadi N, Hashmat N, Rizwan S, Satti NK. Mesenchymal Hamartoma – A Case Report. APMC 2021;15(3):207-209. DOI: 10.29054/APMC/2021.1194

### ABSTRACT

We report a thirteen-month-old female with a history of abdominal distension for two months. She presented to the outpatient pediatric department with pallor, massive abdominal distension, and hepatomegaly. She was initially diagnosed with a liver abscess and admitted to the pediatric ward. Baseline labs, including liver aspirate culture and staining did not reveal any infectious etiology. The patient responded initially to empirical antibiotics, but abdominal distension continued to increase during admission. She was referred to gastroenterology where the investigations showed a solid-cystic liver mass. The patient underwent a surgery for mass excision, and a biopsy revealed mesenchymal hamartoma.

**Keywords:** Abdominal mass, Mesenchymal hamartoma, Abdominal cystic mass.

### INTRODUCTION

Mesenchymal hamartomas are uncommon in children and are mostly present below two years of age. Children present with abdominal distension and accumulation of fluid inside the tumor may lead to respiratory distress in such patients. The histopathology of such tumors shows mostly cystic lesions with solid components as well. These tumors are benign and have an excellent prognosis.<sup>1</sup> They may pose a diagnostic challenge because of their clinical presentation in children below two years. We are presenting a case of mesenchymal hamartoma in a thirteen-month-old girl, including the presenting symptoms and signs along with the diagnostic and therapeutic approach adopted at our center.

### CASE REPORT

A thirteen-month-old female patient presented with abdominal distension for two months. She was in her usual state of health prior to presentation, when she developed rapidly progressive abdominal distension, not associated with any aggravating or relieving factor. There was no history of body swellings at other sites, diarrhea, vomiting, constipation, abdominal pain, jaundice, acholic stools, itching or fever. No urinary symptoms, fits or altered conscious level were reported. Mother also

noticed pallor but there was no history of bruising, rash or bleeding from any site.

The workup was done on an outpatient basis, including ultrasound and CT Abdomen (Figure 1), which showed a provisional diagnosis of hepatic abscess. The patient was admitted to the children's ward of a tertiary care hospital for eight days where she was managed as a case of liver abscess. During the stay, she further developed rapid progression of abdominal distension and ultrasound guided liver drainage was done. 1000 ml of fluid was drained, which was dark yellow in color; 20 ml was sent for analysis (Figure 2) A fluid aspirate from liver showed a proteinaceous background against a few inflammatory cells. Gram staining, Ziehl Nielsen staining, and culture sensitivity of liver aspirate did not reveal any organisms. One packed cell transfusion was given due to low hemoglobin.

The patient was referred to the Pediatric Gastroenterology and Hepatology ward. During the stay, intravenous antibiotics were given and further workup, including MRCP (Magnetic resonance cholangiopancreatography) and MRI were done. Figure 3

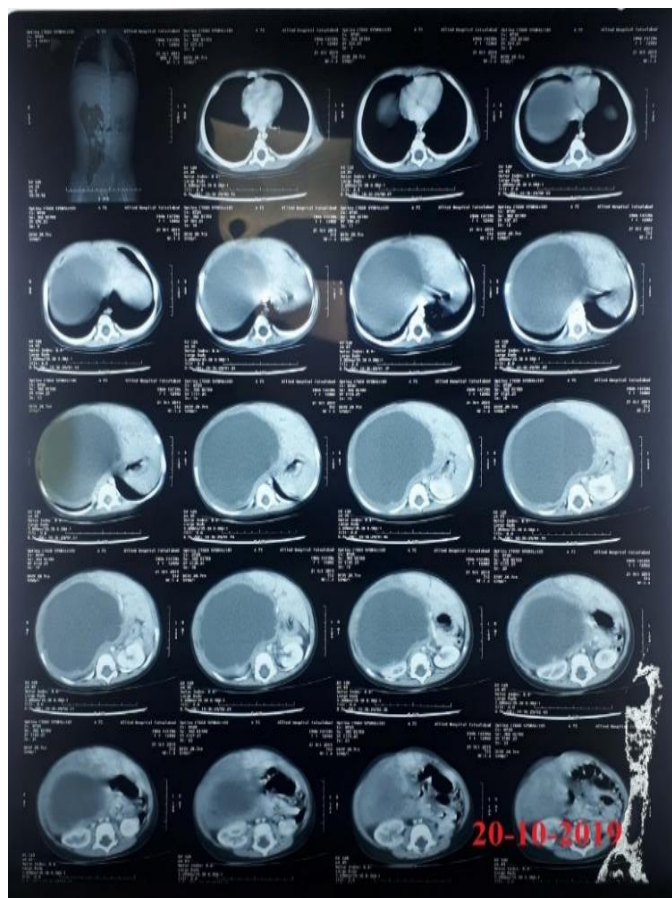
Baseline labs showed a high total leukocyte count in the beginning, which became normal after antibiotics. Electrolytes, renal function, liver function tests and coagulation profile were normal. Antibodies for

Echinococcus were negative. The indirect hemagglutination test for amoebiasis was negative. An ultrasound abdomen revealed an enlarged liver measuring 15 cm and a large fluid collection of about 500-600 ml, having internal debris and a well-defined wall was present in segments V, VI and VII of the liver. No solid mass was seen. MRI abdomen showed a mixed solid-cystic lesion in the right lobe of the liver with internal hyperintense T2W signals.

The collection was drained after consultation with a pediatric surgeon, with the help of a pigtail catheter, which was kept in place. The daily fluid output was about 200 ml /24 hours, which initially was bile stained (and tested positive for bilirubin on dipstick). Later, it was bile free, with the total amount being reduced to 150 ml/24 hours. Abdominal distension had slightly improved over the course of time with no other symptoms. The patient underwent surgery for excision of a solid-cystic mass in the right lobe of the liver. The biopsy specimen turned out to be Mesenchymal Hamartoma.

The post-surgical course was uneventful. Ultrasound after surgical excision showed no mass in the liver. The child is following up in our gastroenterology clinic and is thriving well.

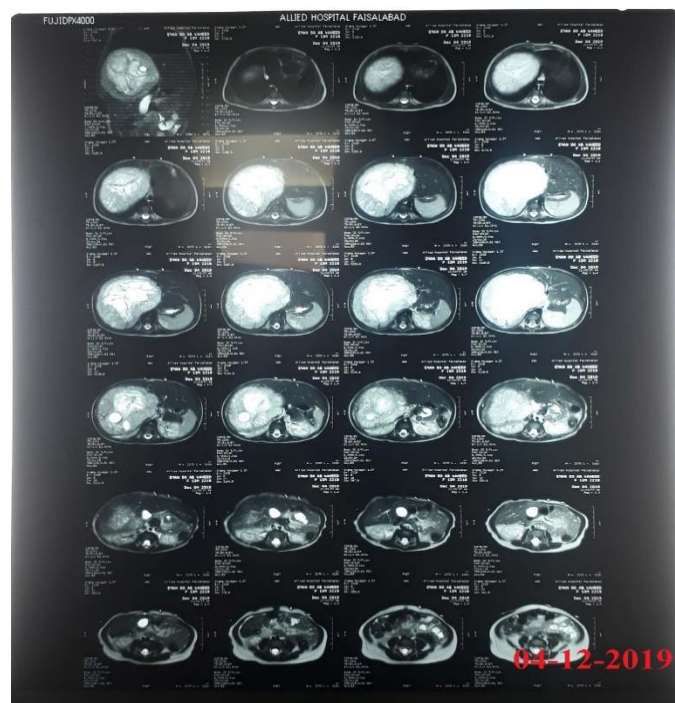**Figure 1: A fluid filled mass in liver**



**Figure 2: Fluid drained before pigtail catheter (1000ml)**



**Figure 3: Solid-cystic mass in liver**



## DISCUSSION

Mesenchymal hamartoma is a rare tumor of benign nature that is derived from the mesenchyme and consists of hepatic cells, blood vessels and bile duct. The tumor has both solid and cystic components with no capsule around it.<sup>2</sup> The porous nature of the tumor allows accumulation of large amounts of fluid inside it and the absence of a capsule allows it to expand and grow to a huge size.<sup>3</sup>

Theories have been proposed regarding the etiology and the factors favouring mesenchymal hamartoma development. It is believed that it is a developmental anomaly resulting from injury and ischemia to the hepatic structures during antenatal life.<sup>4</sup>

Although initially asymptomatic, the tumor can grow massively, leading to pressure symptoms due to compression of the surrounding intra-abdominal structures. The common presenting features are abdominal distension, vomiting, respiratory distress, and constipation. The common examination findings include a palpable mass on the right side of the abdomen.<sup>5</sup> There is a raised level of alpha fetoprotein with normal liver function tests in most cases and radiology of the tumor shows a heterogenous mass with both solid and cystic components in the liver.<sup>6</sup> The standard treatment approach includes surgical resection with clear margins along with supportive care and treatment of complications. The tumor has excellent prognosis with minimal chances of conversion to malignancy.<sup>7</sup>

Mesenchymal tumours are rare and very few cases have been reported in the literature. One such case was reported in India, where a male child presented at thirteen months with abdominal distension, fever, cough and respiratory distress.<sup>8</sup> The child was surgically treated and made a complete recovery. Similar cases have been reported in infants by other authors with complete recovery and no post operative complications and no recurrence on long term follow up.<sup>9</sup>

Very few cases have been reported in neonates. One such case was treated in a three-week neonate with full recovery in a week.<sup>10</sup>

## CONCLUSION

Mesenchymal hamartoma is a rare condition with a favorable prognosis if treated promptly. Misinterpretation of symptoms or radio-pathological

findings can result in unnecessary treatment. Therefore, a thorough understanding of the condition and symptoms is required for positive patient outcomes.

## REFERENCES

1. Apellaniz-Ruiz M, Segni M, Kettwig M, Glüer S, Pelletier D, Nguyen VH, et al. Mesenchymal Hamartoma of the Liver and DICER1 Syndrome. *N Engl J Med*. 2019;380(19):1834-42.
2. Martins-Filho SN, Putra J. Hepatic mesenchymal hamartoma and undifferentiated embryonal sarcoma of the liver: a pathologic review. *Hepatic Oncology*. 2020;7(2):HEP19.
3. Le LT, Phan HT, Nguyen TS, Truong KD, Nguyen DT, Nguyen TB, et al. Infantile mesenchymal hamartoma of the liver with elevated alpha fetoprotein. *BJR case reports*. 2021;6:20200196.
4. Bašković M, Đinkić M, Župančić B, Stepan J, Čizmić L. Torsion of a mesenchymal hamartoma of the liver in a 1-year-old boy. *Acta Chirurgica Belgica*. 2017;117(2):128-30.
5. Rosado E, Cabral P, Campo M, Tavares A. Mesenchymal hamartoma of the liver-a case report and literature review. *J Radiol Case Rep*. 2013;7(5):35-43.
6. Thampy R, Elsayes KM, Menias CO, Pickhardt PJ, Kang HC, Deshmukh SP, et al. Imaging features of rare mesenchymal liver tumours: beyond haemangiomas. *Br J Radiol*. 2017;90(1079):20170373
7. Xu ZL, Wang L, Fan W, Hao ZH, Li C. ALPPS for hepatic mesenchymal hamartoma in an infant. *J Pediatr Surg Case Rep*. 2018;37:70-3.
8. Gupta R, Parelkar SV, Sanghvi B. Mesenchymal hamartoma of the liver. *Indian journal of medical and paediatric oncology: official J Indian Society Medi & Paediat Oncol*. 2009;30(4):141.
9. Maqbool H, Mushtaq S, Hassan U, Ahmad AH, Sarwar S, Sheikh UN. Case series of Mesenchymal Hamartoma: A Rare Childhood Hepatic Neoplasm. *J Gastroint Cancer*. 2020;51(3):1030-3.
10. Hassan MA. Giant solid mesenchymal hamartoma of the liver in a neonate: case report. *Annals of Pediatr Surg*. 2020;16(1):1-4.