

Surgical Management of Inverted Papilloma by Modified Medial Maxillectomy Using Hemi-Midfacial Degloving Approach

Syed Muhammad Ali Tirmizey, Hafiz Sajjad Hyder, Syeda Jamila Ali Tirmizey

ABSTRACT

Background & Objective: The aim of the study was to manage the cases of inverted papilloma using a more conservative approach to determine the morbidity and recurrence. **Study Design:** A prospective study. **Settings:** ENT Unit I Allied Hospital Faisalabad-Pakistan. **Duration:** One-year July 2017 to July 2018. **Methodology:** Modified medial maxillectomy via hemi midfacial degloving approach was done to surgically excise the inverted papilloma. **Results:** No major post-op complication was seen. Patient had markedly reduced morbidity. Recurrence was not observed in follow-up for 6 months to 1 year. The morbidity was minimal as regards the cosmetic appearance and functional preservation. **Conclusions:** The modified approach used in our department is good as regards functional preservation and cosmetic appearance. The approach is relatively easy and does not require sophisticated instruments. Recurrence rate is minimal but long term follow up will better determine the recurrence rate. The approach is worth applicable for further investigation and long term follow up.

Keywords: Inverted papilloma, Prospective study, Morbidity, Recurrence.

Corresponding Author

Submitted for Publication: 15-08-2018

Accepted for Publication: 02-03-2019

DR. HAFIZ SAJJAD HYDER, Senior Registrar, ENT, Faisalabad Medical University, Allied Hospital, Faisalabad-Pakistan

Contact / Email: +92 332-1776566, sajjadhyder292292@gmail.com

Citation: Tirmizey SMA, Hyder HS, Tirmizey SJA. Surgical Management of Inverted Papilloma by Modified Medial Maxillectomy Using Hemi-Midfacial Degloving Approach. APMC 2019;13(1):44-7.

INTRODUCTION

Inverted papilloma (IP) is relatively uncommon benign neoplasm involving the nose and paranasal sinuses.¹ Ward in 1854 studied the macroscopic appearance of papilloma of nose which had a characteristically different appearance from other conditions. He used the term papillomatous neoplasm to describe this lesion. Billroth in 1855 coined the term villous carcinoma to describe inverted papilloma because of its tendency to destroy local tissues and recurrence after surgery. Ringertz in 1938 used the term inverted papilloma after studying the characteristic endophytic growth pattern demonstrated by this type of papilloma. Kramer and Som in 1935 named it genuine papilloma of the nasal cavity. Berendes in 1966 after taking cognizance of the destructive properties of this lesion named it malignant papilloma to indicate this mass.² In 1971 Hyams classified nasal papillomas as inverted papilloma and fungiform papilloma and later including a third group cylindrical papilloma to accommodate the variations seen in these papillomas. Batsakis in 1987 studied the histology of the tumor and named it inverted Schneiderian papilloma due to its origin from Schneiderian mucosa of nose and paranasal sinuses.³ The incidence of IP ranges from 0.2 to 0.6 people diagnosed per 100,000 per year. The most frequently reported complaints are unilateral nasal obstruction and rhinorrhea. The tumour presents mostly in fifth and sixth decade of life and has a predilection for males with a ratio of 3:1.¹ The exact etiology of IP is unclear.²

The treatment of choice of IP is complete surgical removal of the tumor.⁴ Malignancy has been associated in 5–15% of cases which increases with recurrences. This characteristic of IP endorses complete surgical removal of tumors. Krouse Classification is done to grade the disease.² Different approaches have been used to treat IP. At first it involved medial maxillectomy by lateral rhinotomy or midfacial approach.⁴ The extent of surgery has been modified over the years for best possible cosmetic result and minimum recurrence.⁵ Medial maxillectomy is still the treatment of choice. Endoscopic modified medial maxillectomy is now popular in many facilities recently. Endoscopic surgery is showing significantly better treatment outcome in many studies.³ However; endoscopic surgery needs expensive instruments, time and expertise. A large number of surgical techniques are being used to maintain a balance between functional preservation and prevention of recurrence.

The aim of this study was to evaluate the results of a modified medial maxillectomy using hemi midfacial degloving technique as regards tumour recurrence and cosmetic preservation.⁵

METHODOLOGY

Study Design: A prospective study.

Settings: ENT Unit I Allied Hospital Faisalabad-Pakistan.

Duration: One-year July 2017 to July 2018.

Inclusion criteria:

1. All primary cases where no prior surgery was performed.

2. All cases had a preoperative histopathological proven diagnosis of IP.
3. Both Gender were included
4. Patients above 10 years of age and below 70 years of age
5. Primary inverted papilloma of maxillary sinus origin

Exclusion criteria:

1. All recurrent cases
2. Patients of any contraindication to surgery and anesthesia.
3. Less than 10 years of age and above 70 years of age
4. Inverted papilloma primarily arising from ethmoid, sphenoid or frontal sinus.

Methods: 10 patients presenting to Allied hospital with inverted papilloma were included in study. Patients underwent complete clinical investigation followed by surgical treatment using the modified approach.

Complete history, clinical examination and necessary investigations were done. CT scan was done to know extent of the disease. CT scan was done in all cases. Krouse classification was used to grade the tumor. T1 tumor was limited to the nasal cavity, T2 was labelled to the disease which was limited to ethmoid sinuses and medial and superior portions of maxillary sinuses, in T3 the disease involved the lateral or inferior aspects of maxillary sinus or extension into frontal or sphenoid sinuses and T4 tumor went outside the confines of nose and sinuses. The surgical excision was done by hemi mid-facial degloving approach. This method involves a gingivobuccal incision across the midline made from the ipsilateral third molar to the contra-lateral first incisor across the midline, a septal transfixion incision, a pyriform aperture incision, and a lateral osteotomy along the frontal process of the maxilla to the nasion. The cheek flap was developed with subperiosteal dissection exposing the maxilla, the premaxilla, and the pyriform aperture. Alar cartilage and columella were lifted only on the effected side. The infraorbital nerve was identified after raising the cheek flap. Extended Caldwell Luc was performed to expose the tumor completely. The bone involving front of maxilla and medial wall was removed. Inferior turbinate and part of lateral nasal wall mucosa was removed with widening of ostium. The infraorbital nerve was saved and tumor was removed completely. All the involved sinuses and nasal cavity was cleared of any disease. The inferior turbinate along with the mucosa of medial wall of maxillary sinus was removed. The orbital rim was saved. Wound was closed in layers after meticulous hemostasis and nasal packing was done. This approach gave direct visualization of the ethmoid, sphenoid and maxillary sinus along with nasopharynx and nasal cavity. The hemi mid-facial degloving approach avoids unnecessary exposure of the healthy side of the midface, and avoids vestibular stenosis. The procedure was analyzed for functional preservation and recurrence on follow up.

RESULTS

10 cases were studied and we analyzed these 10 cases of inverted papilloma regarding its incidence, age and sex ratio, symptomatology, extent of disease, recurrence rate and rate of malignancy.

Table 1: Age distribution

Age	No. of Patient	Percentage
20-30	1	10%
31-40	5	50%
41-50	3	30%
51-60	None	None
61-70	1	10%

According to our study the mean age of presentation was 42.4 with earliest the case being of a 28-year-old male. Most patients were in between the age of 31-40.

In our study was contrary to the average sex incidence in other studies. In our study there was female predominance.

Table 2: Gender distribution

Gender	No. of Patient	Percentage
Female	7	70%
Male	3	30%

Female to male ratio in our study is 2.3:1

Symptoms were noted down in each case with most frequent being nasal obstruction with rhinorrhea and epistaxies.

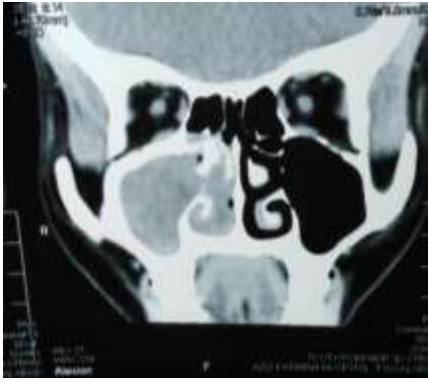Table 3: Symptomatology

Symptomatology	No.	Percentage
Nasal obstruction	10	100%
Epistaxis	9	90%
Discharge	9	90%
Proptosis	2	20%
Swelling over cheek	1	10%
Numbness over cheek	1	10%

All the patients were graded on Krouse classification. 6 patients had T2 stage, 2 patients had T3 and 2 had T4.

Table 4: Krouse classification

Number of patients	Stage of Krouse classification	Percentage
none	Stage T1	0%
6	Stage T2	60%
2	Stage T3	20%
2	Stage T4	20%



This is a coronal section through Plain CT scan nose and PNS of a patient with T2 krouse classification

Patient was called for follow-up and following complications were noted.

Table 5: Complications

Complications	No. Patients	Percentage
Post-op bleeding/epistaxis	2	20%
Transient malar paresthesia	8	80%
Permanent malar paresthesia	1	10%
Facial Asymmetry/Vestibular stenosis	0	0
Epiphora	1	10%
Atrophic Rhinitis	1	10%
Recurrence	0	0

Most of the complications were temporary and no recurrence was seen after a follow-up of 6 months to 1 year however; a long period of follow-up is required to evaluate recurrence rate. There was no severe bleeding during surgery or after surgery. Vestibular stenosis or cosmetic disfigurement did not occur in any of the 10 patients. Unilateral lateral osteotomy did not affect the symmetry of the bony nasal pyramid. 8 of the 10 patients complained of paresthesia over the cheek which was transient and was a common complication related to the sub labial or gingivobuccal incision.

Malignancies: Post-op biopsy of excised specimen confirmed inverted papilloma. One patient had areas of dysplasia. The areas of dysplasia had moderately differentiated squamous cell carcinoma in between them. One patient had non-keratinizing squamous cell carcinoma inverted type.

Recurrence analysis: No recurrence was reported; Post-op endoscopies were done and follow-up CT scan 6 months after surgery was done. The duration of study is only 1 year so to confirm recurrence we have to have a long follow up.

Post-op morbidity: All the patients were counselled about the surgery and possible outcomes. After the surgery, pack was removed on 2nd post-op day. No significant bleeding or facial deformity was seen. All patients were discharged after 5th Post-op day. Patients didn't have any facial scar. Paresthesia was transient which resolved within 3 months.



Pre-op picture 3rd day Post-op picture of the same patient

Above is a picture of the patient included in the study. No significant facial deformity was seen. The tumor mass was successfully excised with modified medial maxillectomy. This conservative approach towards IP led to significantly reduced morbidity and hospital stay.

DISCUSSION

The Sino nasal inverted papilloma is not an uncommon disease arising from Schneiderian membrane.⁶ The incidence of inverted papilloma presenting to Allied hospital has increased significantly in past 5 years which is why we conducted this study for the best management of the disease keeping in view the limitations in our facility. Complete history, clinical examination and necessary investigations were done.

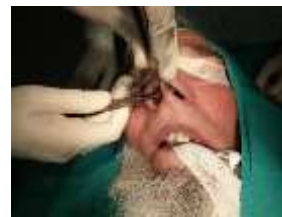

Figure 1: Trans fixation incision

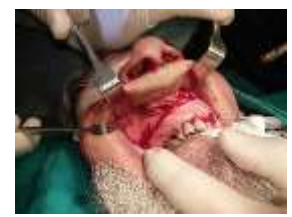

Figure 2: sub labial modified incision

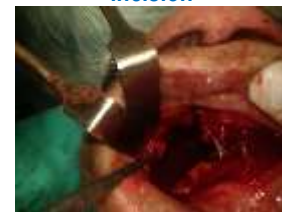

Figure 3: modified medial maxillectomy

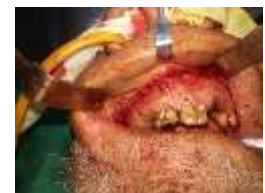

Figure 4: wound closed in layers (note the cosmetic result)

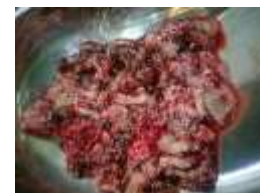

Figure 5: specimen collected

According to our study the mean age of presentation was 42.4 with earliest case being of a 28-year-old male. Most patients were in between the age of 31-40. (Table 1). It is lower than the

age mentioned in literature,^{1,7} however, due to small sample size definite age of presentation in Faisalabad needs further research. In contrast to most literatures^{1,8,9} the incidence of inverted papilloma is more in females with a 2.3:1 female to male ratio (Table 2). However again due to small sample size we can't say for sure if this reflects the true gender distribution in our district. Further research will help determine the true gender distribution of IP. Symptomatology of the patients was studied. Nasal discharge, nasal obstruction and epistaxis were the most common complaints (Table 3) This compares favorably with most other studies.^{1-4,10} CT scan was done to evaluate the site of origin shown by hyperostosis. Krouse classification was done and 60% patients had T2 stage (Table 4). Post-op complications were noted (Table 5). No major facial deformity was seen. Temporary malar paresthesia was seen as a result of midfacial degloving approach which resolved over a period of 3 months. No recurrence was seen however; the study period was only 1 year. Further follow up will reveal the recurrence rate of our approach.

We have devised a new method of conservative open approach. It involves hemi mid-facial degloving approach on the affected side and modified medial maxillectomy saving the infra-orbital nerve and orbital rim. This is more like an extended Caldwell Luc procedure. The site of origin (as indicated by hyperostosis in CT) was then removed, cauterized or drilled to decrease recurrence rate. The wound was closed after packing.

CONCLUSION



Inverted papilloma is not an uncommon pathology. Every patient with unilateral mass must be investigated for IP. The modified approach used in our department is good as regards functional preservation and cosmetic appearance. The approach is relatively easy and does not require sophisticated instruments. Recurrence rate is minimal but long term follow up will better

determine the recurrence rate. The approach is worth applicable for further investigation and long term follow up.

REFERENCES

1. Lisan, Q, Laccourreye O, & Bonfils P. Sinonasal inverted papilloma: From diagnosis to treatment. Eur Ann Otorhinolaryngol Head Neck Dis. 2016;133(5):337-341.
2. Lisan Q, Moya-Plana, A, & Bonfils, P. Association of Krouse Classification for Sinonasal Inverted Papilloma with Recurrence. JAMA Otolaryngol Head Neck Surg. 2017;143(11):1104-10.
3. Pagella F, Pusateri A, Matti E, Avato I, Zaccari D, Emanuelli E, Tomacelli GL. "TuNa-saving" endoscopic medial maxillectomy: a surgical technique for maxillary inverted papilloma. Eur Arch Otorhinolaryngol. 2017;274(7):2785-91.
4. Yildirim V, Pausch NC, Halam D, Lübbers HT, & Yildirim A. Is radical surgery of an inverted papilloma of the maxillary sinus obsolete? a case report. J Med Case Rep. 2016;10(1):341-8
5. Healy DY, Chhabra N, Metson R, Holbrook EH, & Gray ST. Surgical risk factors for recurrence of inverted papilloma. Laryngoscope. 2016;126(4):796-801.
6. Mirza S, Bradley PJ, Acharya A, Stacey M, Jones N.S. Sinonasal inverted papillomas: recurrence, and synchronous and metachronous malignancy. J Laryngol Otol. 2007;121(9):857-64.
7. Yoon JH, Kim CH, Choi EC. Treatment outcomes of primary and recurrent inverted papilloma: an analysis of 96 cases. J Laryngol Otol. 2002;116(9):699-702.
8. Raveh E, Feinmesser R, Shpitzer T, Yaniv E, Segal K. Inverted papilloma of the nose and paranasal sinuses: a study of 56 cases and review of the literature. Isr J Med Sci. 1996;32(12):1163-7.
9. Jeon SY, Jeong JH, Kim HS, Ahn SK, & Kim JP. Hemifacial Degloving Approach for Medial Maxillectomy: A Modification of Midfacial Degloving Approach. Laryngoscope. 2003;113(4):754-6.
10. Karkos PD, Khoo LC, Leong SC, Lewis-Jones H, Swift AC. Computed tomography and/or magnetic resonance imaging for pre-operative planning for inverted nasal papilloma: review of evidence. J Laryngol Otol. 2009;123(7):705-9.

AUTHORSHIP AND CONTRIBUTION DECLARATION

AUTHORS	Contribution to The Paper	Signatures
Dr. Syed Muhammad Ali Tirmizey Professor of ENT Faisalabad Medical University, Faisalabad	Introduction, Data Collection, Discussion	
Dr. Hafiz Sajjad Hyder Senior Registrar, ENT Allied Hospital, Faisalabad	Data Analyzing, References	
Dr. Syeda Jamila Ali Tirmizey Post Graduate Trainee, ENT Allied Hospital, Faisalabad	Results, Tables	